Open Access

SCHOLARENA

Journal of Orthopaedics and Bone Research

RESEARCH ARTICLE

Vascularized Bone Graft of Zaidemberg in the Upper Pseudarthrosis of the Scaphoid

Meziani N*

Faculty of Medicine, Department of Orthopaedic and Traumatological Surgery, CHU of Bab El-oued, Algiers, Algeria

***Corresponding author:** Meziani N, Faculty of Medicine, Department of Orthopaedic and Traumatological Surgery. CHU of Bab El-oued. Algiers. Algeria, Tel: +213(0)561234233, E-mail: nassimameziani@yahoo.fr

Citation: Meziani N (2022) Vascularized Bone Graft of Zaidemberg in the Upper Pseudarthrosis of the Scaphoid . J Orthop Bone Res 3: 101

Abstract

The authors studied the results of a series of 11 cases concerning the vascularized bone graft of Zaidemberg in scaphoid pseudoarthrosis. This graft is indicated in case of proximal or old nonunion, or in the presence of proximal polar necrosis. This graft gives a better rate of consolidation of pseudoarthrosis compared to conventional grafts and also remains a suitable solution and rescue during a surgical recovery.

Keywords: Pseudoarthrosis of the Scaphoid; Vascularized Bone Graft; Superior Pole; Poor Vascularization

Introduction

Carpal scaphoid fractures evolve in 10% of cases towards pseudarthrosis [1-3]. When the pseudoarthrosis is located at the proximal pole, given the precarious vascularization at this level, it may be associated with superior polar devascularization or even necrosis. If left untreated, it may progress to degenerative osteoarthritis of the wrist [4-8].

The appearance of vascularized bone grafts has led to a rethinking of the management of pseudarthrosis. The literature has demonstrated a significantly higher rate of consolidation in patients with necrosis of the proximal pole of the scaphoid with these vascularized grafts [9-10]. In this indication, they are generally recommended. Indeed, they would facilitate consolidation and bone revascularization. They would have a biological and mechanical superiority over conventional grafts. Thus, when there is necrosis of the proximal pole, the consolidation rates seem to be higher than with conventional grafts [11].

In 1991, Carlos Zaidemberg of Argentina [12] described a new technique for scaphoid repair using vascularized graft taken from the radial styloid. We wanted to verify these data by studying the results of this type of graft performed in our department.

Materials and Methods

11 scaphoid pseudarthroses treated with Zaidemberg graft [12] between 2007 and 2014 were studied retrospectively with a mean follow-up of 3.5 years (9 months - 6.5 years).
Among them ,2 patients benefited from palliative surgery after failed consolidation.
We operated on 7 scaphoids on the right side and 5 scaphoids on the left side.
In 8 cases it was the dominant hand
There was a clear male predominance (10 men and 01 woman).
No patient had any comorbidities.
07 patients (men) used tobacco.
The average age of the patients at the time of the accident was 26 years (18-45 years)
The average age of the patients at the time of the intervention was 29 years (19-48 years)
The average time from injury to management was 3 years (6 months-6 years)
The main cause of the fracture at the time of the initial accident was:
A work accident (08cas)
Sports accident (03 cases)
According to Schernberg's classification (8), the pseudoarthrosis was located in zone 3 in 8 cases and in zone 2 in 3 cases.
We had 8 cases of stage 2a and 3 cases of stage 2b according to the Alnot classification [1,2].

The diagnosis of necrosis was retained 7 times (Figure 1), in case of fragmentation of the proximal pole, absence of enhancement of the latter after injection of gadolinium on MRI, or by the absence of bleeding, or by a white and chalky aspect, the consistency of the bone according to Green's intraoperative criteria [6].

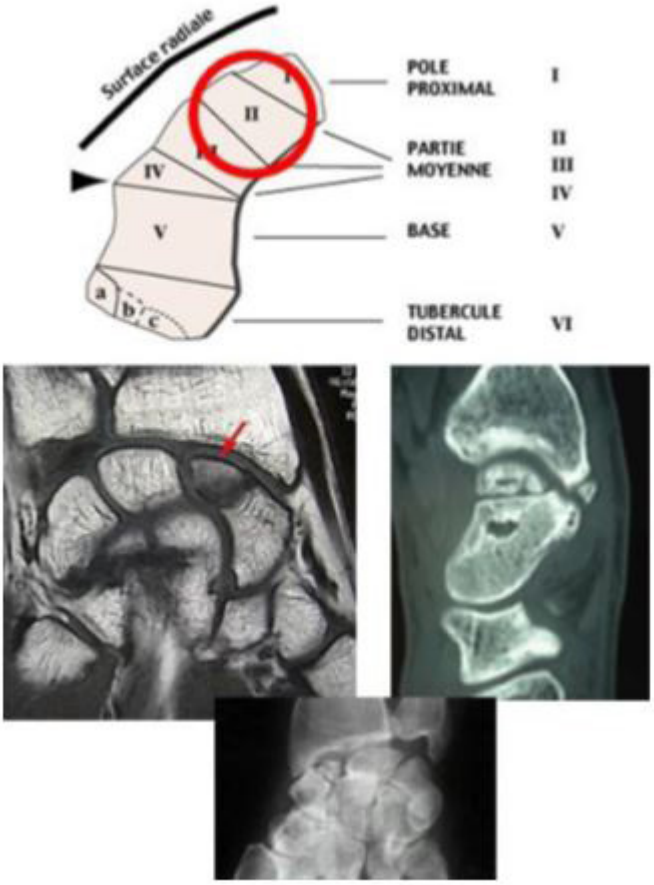

Figure 1: Concept of polar necrosis

The principle of the operation was to incarcerate a dorso-radial bone graft in the previously cured pseudarthrosis site, pedicled on the supra-retinacular artery of the radius. Osteosynthesis was performed with pins followed by immobilization until radiological consolidation of the pseudarthrosis site.

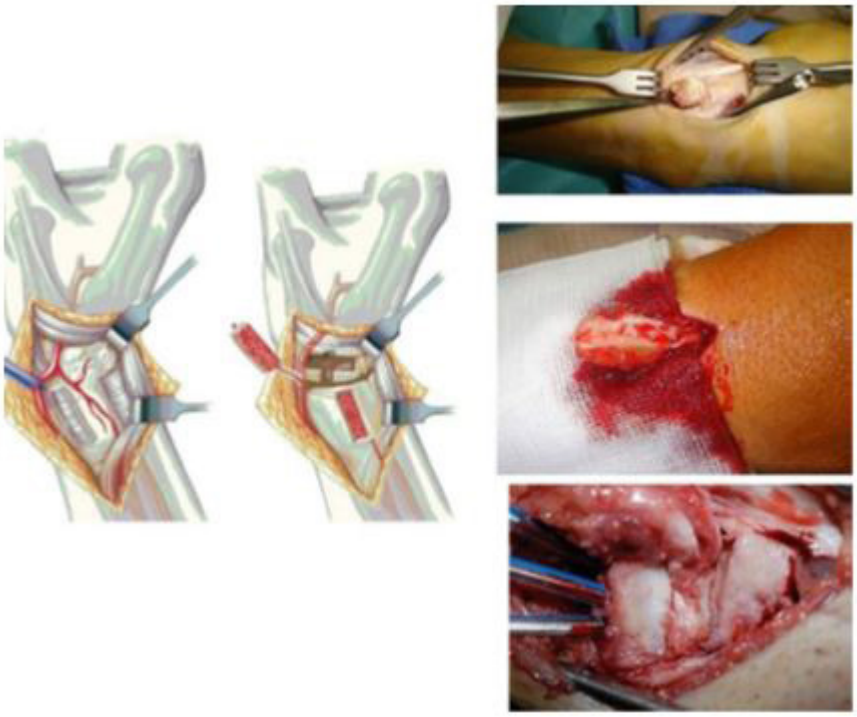

Figure 2: Surgical technique

After a dorso-radial, longitudinal, straight approach, centered on the radiocarpal space and careful control of the radial nerve branches, the supraretinacular artery (SRA) is exposed. Opening of the first two extensor compartments on either side of the path of the artery always. A longitudinal arthrotomy in the axis of the second compartment is performed and then the capsuloperiosteal flap is removed. De-periostealization and styloidectomy are performed while protecting the graft pedicle. Elevation of the pseudarthrosis site, harvesting of the cortico-cancellous graft, which must be cut to the right dimensions by an osteotomy centered on the ASR, which will be incorporated into the scaphoid by spreading its 2 fragments with a foam spatula. Osteosynthesis by 2 wires inserted from the isthmus of the scaphoid. Their orientation through the graft to the proximal pole is done under permanent visual control. Closure without drainage after hemostasis and removal of the tourniquet. Segmental splinting to immobilize the wrist for 3 weeks, followed by a resin glove for 8 to 10 weeks, depending on the radiological evolution.

On average, 9 out of 11 patients consolidated in 8.5 weeks.
The average duration of immobilization was 8 weeks with a resin BAP.
Postoperative rehabilitation also lasted 12 weeks.
No patient required vocational retraining

Results

The clinical criteria studied were: joint amplitudes, wrist strength, the Quick Dash which was 12%, the PRWE questionnaire which includes 15 questions with a total score reported at 100, it reflects the inability of the patient to use his operated wrist in comparison with the healthy side. and the Mayo Wrist Score combining a subjective and objective functional evaluation by studying the intensity of the pain, the ability to return to work, mobility and strength. (Figure 3).

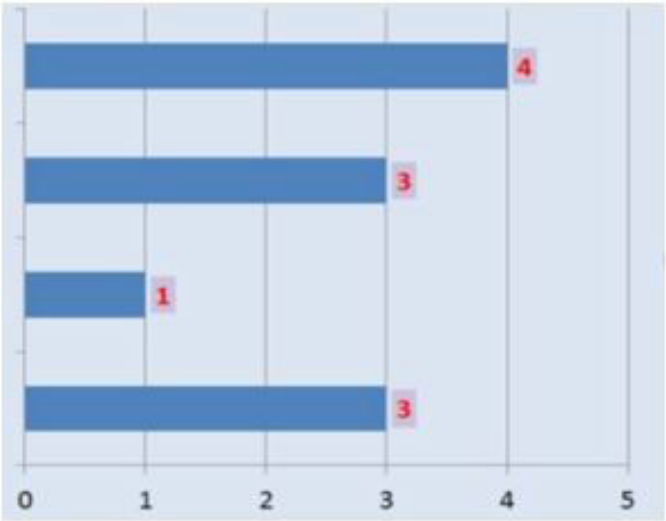

Figure 3: Overall results. Mayo clinic

4-Excellent
3-Good
1-Average
3-Poor

Overall, the clinical results are comforting in more than one way, since there was a clear improvement in all the clinical evaluation parameters, the arc of mobility in flexion-extension went from 77° preoperatively to 101° postoperatively, as well as the strength of the hand, which improved from 39% to 60%, explained by the reduction in pain (Figure 4).

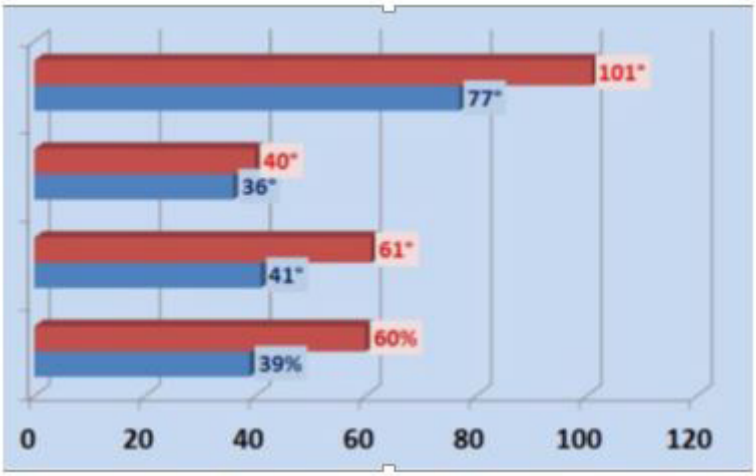

Figure 4: The clinical results

Preoperative
Post operative

The radiographic workup allowed us to monitor the consolidation. On review of the literature, our results on consolidation are close to the worldwide data, as summarized in the table comparing the results of the various authors (Figure 5). We observed 9 consolidations out of 11 in 8.5 weeks on average.

Séries	Année	Nbre de patients	Consolidation
Zaidemberg	1991	11	100%
Tsai	2002	5	100%
Waters	2002	3	100%
Uerpairojkit	2000	10	100%
Malizos	2001	22	100%
Steinmann	2002	14	100%
Waitayawinyu	2009	30	93%
Chang	2006	48	71%
Boyer	1998	10	60%
Straw	2002	22	27%
Pedeutour	2013	87	74%
Notre série	2014	11	82%

Figure 5: Review of the Literature

The criterion for analysis of bone consolidation was strict: consolidation was considered effective in the absence of interfragmentary deviation at the pseudarthrosis site, in the absence of movement of the material or a lysis chamber around it, and in the absence of progressive displacement of the graft. The two failures in consolidation were explained by malposition of the graft. From the global result point of view, our patients had an average Mayo Wrist Score of 78%. The three poor results were explained by the unfavorable evolution of the two pseudarthroses that did not consolidate and by one pseudarthrosis that finally consolidated but retained poor wrist mobility and persistent pain.

Discussion

In cases of prolonged pseudarthrosis or necrosis of the proximal pole, the results with vascularized grafts are better compared with conventional bone grafts especially the Matti-Russe technique.

Recently, experimental studies have shown that in a poor quality recipient site, incorporation of a vascularized graft was better than that of a non-vascularized graft. These well-known studies have also shown that revascularization of a bone was facilitated by a vascularized graft and that consolidation was faster [3,4].

Since Zaidemberg's description [12], the supraretinacular artery-based graft has been increasingly used in scaphoid pseudarthrosis, with variable consolidation rates depending on the series, generally exceeding 90% consolidation. Zaidemberg's series [12], consisting of 11 patients, shows a 100% consolidation rate in 6.2 weeks.

The meta-analysis by Merrell [11] found a consolidation rate of 47% with conventional grafts in 64 patients with vascular necrosis of the proximal pole, rising to 88% with a vascularized graft. Our results appear to be consistent with those reported in the literature, which are summarized in Table 1.

The dorso-radial approach used in the Zaidemberg technique [12] is untouched by any intervention, and is a valuable advantage. This approach gives access to the graft harvesting site in the immediate vicinity of the reconstruction site. It allows for graft harvesting and treatment of the pseudarthrosis in the same operating time (minor morbidity, aesthetic advantage). The anatomy of the supraretinacular artery is constant, which allows for a reliable and reproducible technique. Morbidity at the donor site using a minor vascular axis is therefore minimal and the pedicle is long enough to reach the pseudarthrosis without the slightest tension. This harvesting procedure allows us to dispense with general anesthesia, with the possibility of outpatient treatment under locoregional anesthesia [13].

Graft harvesting thus allows a shorter operating time, but for iliac harvesting, there are risks of haematoma, which may become infected, and of fracture of the iliac wing, which may cause pain and injury to the femoral-cutaneous nerve [14-16].

The major concern is in the manipulation to adapt it to the bone loss because of the risk of injury to the pedicle. Indeed, a free graft is easier to cut to the desired shape than a pedicled graft [16]. Its embedding in the scaphoid also remains a difficulty. The graft cannot be impacted at the recipient site, as one would impact a non-vascularized graft, an impaction could damage the pedicle and consequently compromise the vitality of the graft in addition a graft of radial origin is more friable and less consistent than an iliac graft [14,15].

Conclusion

Our results on a series of 11 cases concerning the vascularized Zaidemberg bone graft in scaphoid pseudarthrosis are consistent with those in the literature. This graft is indicated in cases of proximal or old pseudarthrosis, or in the presence of proximal polar necrosis. It allows for better consolidation of pseudarthrosis than conventional grafts. It is thus a suitable solution for revision surgery.

The Zaidemberg graft [12] improves the radiometry of the carpus and seems to prevent arthrosis. (Figure 6).

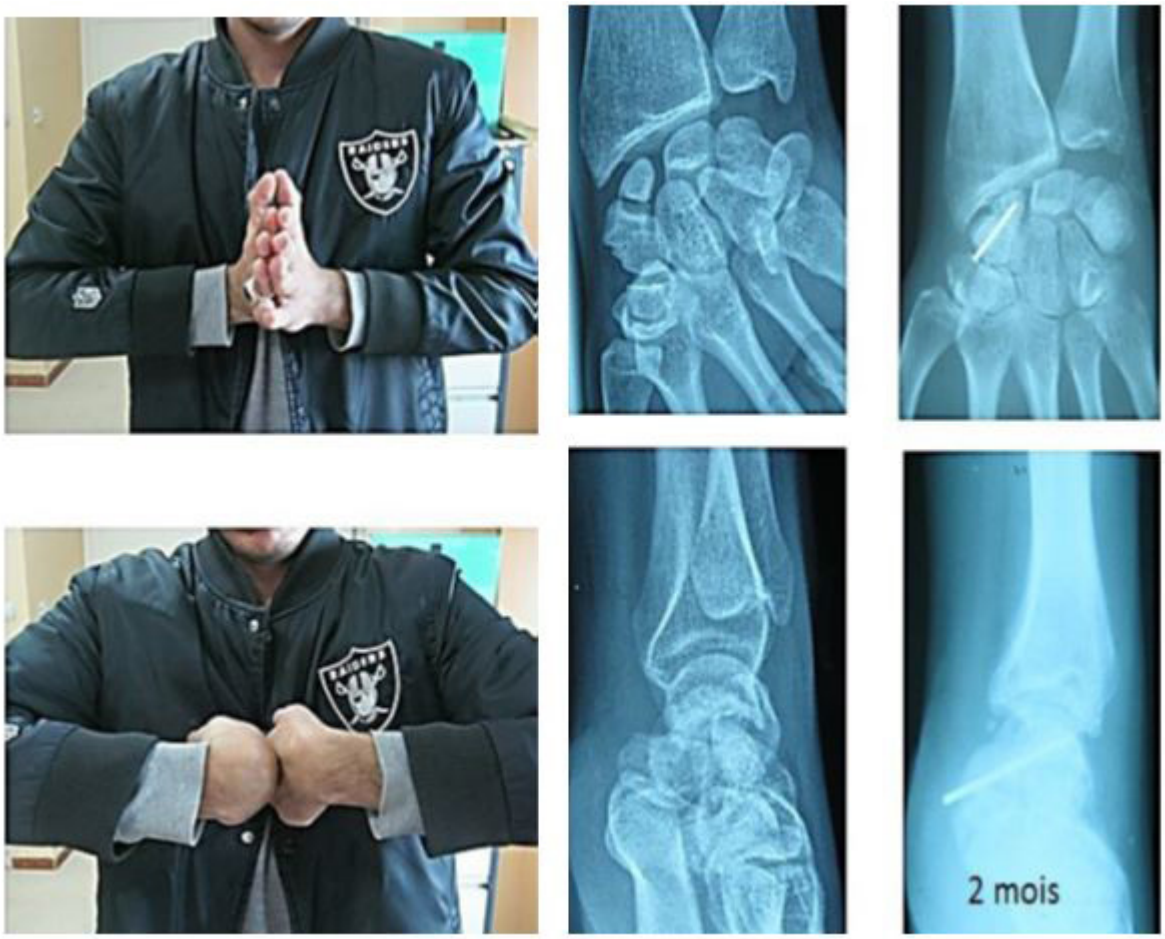

Figure 6 : of a patient aged 24

Clinical case.40 months after the trauma
Normo centric aspect of the lunate
Absence of arthrosis

This procedure remains difficult and therefore requires a learning curve. Given the difficulties in harvesting the graft, the persistence of its vascularization after osteosynthesis remains an uncertainty. The series concerning vascularized grafts do not allow us to affirm the persistence of vascularization during the bone consolidation process [23].

References

1. Alnot JY (1988) [Fractures and pseudarthroses of the carpal scaphoid. The various stages of pseudarthrosis]. Rev Chir Orthop Reparatrice Appar Mot 74: 714-7.

2. Alnot JY (1988) Symposium sur les fractures et pseuarthroses du scaphoïde carpien. 74: 714-7.

3. Berdia S, Wolfe S (2001) Effects of scaphoid fractures on the biomechanics of the wrist. Hand Clin. 17: 533-40.

4. Boyer MI, von Schroeder HP, Axelrod TS (1998) Scaphoid nonunion withavascular necrosis of the proximal pole. Treatment with a vascularizedbone graft from the dorsum of the distal radius. J Hand Surg 23: 686-90.

5. Gelberman RH, Menon J (1980) The vascularity of the scaphoid bone. J Hand Surg Am 5: 508-13.

6. Green DP (1985) The effect of avascular necrosis on Russe bone grafting for scaphoid nonunion. J Hand Surg Am 10: 597-605.

7. Saffar P (2008) Malunion of the scaphoid. Hand Surgery 27: 65-75.

8. Schernberg F (1988) [Classification of fractures of the carpal scaphoid. An anatomo-radiologic study of characteristics]. Rev Chir Orthop Reparatrice Appar Mot 74: 693-5.

9. Uerpairojkit C, Leechavengvongs S, Witoonchart K (2000) Primary vascularized distal radius bone graft for nonunion of the scaphoid. J Hand Surg [Br] 25: 266-70.

10. Malizos KN, Dailiana ZH, Kirou M, Vragalas V, Xenakis TA, et al. (2001) Long standing non unions of scaphoid fractures with bone loss: successful reconstruction with vascularized bone grafts. J Hand Surg Br 26B: 330-4.

11. Merrell GA, Wolfe SW, Slade JF (2002) Treatment of scaphoid nonunions: Quantitative metaanalysis of the literature. The J Hand Surg 27: 685-91.

12. Zaidemberg C, Siebert JW, Angrigiani C (1991) A new vascularized bone graft for scaphoid nonunion. J Hand Surg Am 16: 474-8.

13. Saint Cast Y, Césari B, Dagregorio G, Le Bourg M, Gazarian A, et al. (2012) Technique simplifiée de reconstruction du scaphoïde par le greffon vascularisé radial de Zaidemberg. Revue de Chirurgie Orthopédique et Traumatologique 98: S167-73.

14. Chang MA, Bishop AT, Moran SL, Shin AY (2006) The outcomes and compli-cations of 1,2-intercompartmental supraretinacular artery pedicled vascu larized bone grafting of scaphoid nonunions. J Hand Surg [Am] 31: 387-96

15. Obert L, Lemaire B, Lepage D, Clappaz P, Garbuio P, et al. (2007) Analyse des échecs du greffon vascularisé de Zaidenberg en cas de pseudarthrose du scaphoïde : difficultés technique ou erreur chirurgicale ? Revue de Chirurgie Orthopédique et Réparatrice de l'Appareil Moteur 93: 140-1.

16. Chantelot C, Frebault C, Limousin M, Robert G, Migaud H, et al. (2005) [Long-term outcome of non-vascularized grafts for carpal scaphoid nonunion : 58 cases with 8.8 year follow-up]. Rev ChirOrthopReparatriceAppar Mot 91: 724-31.

17. Steinmann SP, Bishop AT, Berger RA (2002) Use of the 1, 2 intercompartmental supraretinacular artery as a vascularized pedicle bone graft for difficult scaphoid nonunion. J Hand Surg [Am] 27A: 391-401.

18. Straw RG, Davis TRC, Dias JJ (2002) Scaphoid non union : treatment with a pedicled vascularized bone graft based on the 1, 2-intercompartmental supraretinacular branch of the radial artery. J Hand Surg Br 27B: 413-6.

19. Waitayawinyu T, McCallister WV, Katolic LI, Schlenker JD, Trumble TE (2009) Outcomes after vascularized bone grafting of scaphoid nonunions with avascular necrosis. J Hand Surg [Am] 34A: 387-94.

20. Tsai TT, Chao EK, Tu YK, Chen ACY, Lee MSS, et al. (2002) Management of scaphoid non union with avascular necrosis using 1, 2 intercompartmental supraretinacular arterial bone grafts. Chang Gung Med J. 25: 321-8.

21. Waters PM, Stewart SL (2002) Surgical treatment of nonunion and avascular necrosis of the proximal part of the scaphoid in adolescents. J Bone Joint Surg Am. 84A: 915–20.

22. Pedeutour B. « Results of 87 vascularized Zaidemberg bone grafts in scaphoid pseudarthrosis, retrospective study ». Thèse 2013. Faculty of Medicine of Nancy.

23. Shin AY, Bishop AT (2002) Pedicled vascularized bonegrafts for disorders of the carpus: scaphoid nonunion and Kienbock's disease. J Am Acad OrthopSurg 10: 210-6.