Open Access

SCHOLARENA

Journal of Biomedical Studies

RESEARCH ARTICLE

Variations in the Branching Pattern and Position of the Aortic Arch in Southern Nigeria using Computed Tomography Scans: A Retrospective Study

Odey PA[1], Akpaso MI[1], Ogan CA[2], Ajang CU[1] and Ikpa JO[2*]

[1]Department of Anatomical Sciences, College Of Medicine, University of Calabar, Calabar-Nigeria.

[2]Department of Anatomy and Forensic Anthropology, Faculty of Basic Medical Sciences Cross River University of Technology (Crutech), Calabar-Nigeria.

[*]**Corresponding author:** Ikpa JO, Department of Anatomy and Forensic Anthropology, Faculty of Basic Medical Sciences Cross River University of Technology (Crutech), Calabar-Nigeria,, Tel: +2347089418231, E-mail: jamesonahikpa@gmail.com

Citation: Odey PA, Akpaso MI, Ogan CA, Ajang CU, Ikpa JO (2021) Variations in the Branching Pattern and Position of the Aortic Arch in Southern Nigeria using Computed Tomography Scans: A Retrospective Study. J Biomed Stud 1: 102

Abstract

Background: Medical and surgical pathologies involving the arch of aorta are on the rise. Cardiothoracic surgeons as well as physician cardiologists have sought solutions to alleviate complications arising from procedures involving the aortic arch with limited studies available especially in Nigeria spurring the need to investigate the variations existing in the branching patterns as well as position of the arch of aorta in some states in South-South region of Nigeria.

Aim: The study seeks to determine the anatomical variation in the branching pattern and position of aortic arch in some South-South States in Nigeria using computed tomography.

Material and Methods: 200 retrospective tomographs from Computed tomography (CT) scans were used for data collection and tomographs met all the inclusion criteria. 108 were males while 92 were females. With the use of DICOM software, images were reviewed accordingly and the branching patterns as well as position were noted. The ages ranged from 26 to 72years, with a mean age of 51.21years, SEM of 0.85 and SD of 12.02.

Results: Out of 200 [100%] subjects, none presented with an abnormal aortic position as all were found to be placed in the superior mediastinum slightly above the transverse thoracic plane of Ludwig. Conversely, out of the 200, 196 (98%) presented with the classical branching pattern while 4 (2%) presented with variant branching pattern, interestingly, all 4 (2%) were reportedly males.

Conclusion: No variation in the position of aortic arch was seen in this study; however, there were few variations in the branching patterns which occurred in male subjects predominantly.

Keywords: Variations; Aortic Arch, Branching Pattern, South-South, Nigeria, Computed Tomography.

Introduction

In Medical and surgical pathologies involving the arch of aorta are on the rise. Globally, there is paucity of investigations carried out on the variations in aortic arch in both branching pattern and position. Nevertheless, the increasing rate of both medical and surgical pathologies involving the cardiovascular system has propelled further research in the developmental and adult anatomy of the aortic arch.

The thoracic aorta can be divided into ascending aorta, arch of aorta and the descending aorta. The arch of aorta is found in the superior mediastinum and begins when the ascending aorta emerges from the pericardial sac and courses upward backward and to the left as it passes through the superior mediastinum. It ends at the left side at thoracic vertebral level four and five [T4/T5], extending as high as the midlevel of the manubrium sterni [1].

The position of deep structures in the thorax is usually described in relation to cartilaginous or bony landmarks such as the manubrosternal joint, second costal cartilage which is in turn referenced to the intervertebral disc between fourth and fifth thoracic vertebrae [T4/T5] all of which forms the diameter of the chest [1] such as the beginning and end of arch of aorta and bifurcation of the trachea(carina), the imaginary boundary separating the superior from the inferior mediastinum, the loop of recurrent laryngeal nerve under the aortic arch, bifurcation of the pulmonary trunk [2].

Factors responsible for the variations in position and branching pattern of the arch of aorta include a default in the embryological development of the aortic arch. Following a progress in cardiovascular morphogenesis, an organized patterned progress of regression and growth of the components of pharyngeal arches lead to a definitive configuration of the thoracic aorta and its branches. A fully developed aortic arch is left sided and gives rise to the right sided brachiocephalic trunk which branches into right common carotid and right subclavian arteries, the left common carotid and left subclavian artery.

Persistence or regression of any of the segment of aortic arch system results in an extensive aortic arch anomaly and consequently a variation. The variations that may exist following malformations include: right sides aortic arch, double aortic arch, right aortic arch with abnormal branching, left aortic arch with abnormal branching and cervical aortic arch.

Evidence from human genetic and animal studies suggested that chromosome 22q11 deletions may be an important cause of anomalous development of the aortic arch [3]. This was also noted by Momma *et al.,* (1999) [4] that the aortic arch anomalies are associated with chromosome 22q11 deletion [4]. Nevertheless, anomalous origins of the aortic arch branches are anatomic variants hence, accurate information about them is vital for vascular surgery in the thorax, head and neck region [5].

A study on the "Anatomical variations in the branching of the human aortic arch" using radiological methods showed that out of 94 patients, within the age range 31-86 who had no problems related to the aortic arch,74.46% had the classical branching pattern designated as type A [comprising the right sided brachiocephalic trunk, left common carotid artery and left subclavian artery]. Other variants in branching pattern were designated type B to type G with the following percentage variation: 14.91%, 4.25%, 2.13%, 2.13%, 1.06% and 1.06% respectively [6].

Similarly, there was a study on "Anatomy and Radiology of the variations of aortic arch branches in 1226 patients" [7]. Eight branching patterns were discovered here including the classical branching pattern.

Aortic variation in position is also referred to as a cervical aortic arch and it is characterized by an aortic arch extending abnormally high in the neck, occurring more commonly on the right [8]. Proposed theories to explain the development of cervical arches include development of the cervical arch from the second or third primitive arches with regression of the fourth arch and failure of normal caudal descent of an otherwise normal fourth aortic arch [8,9,10].

Computed tomography scan (CT scan) makes use of computer-processed combinations of many X-ray measurements taken from different angles to produce cross-sectional (tomographic) images (virtual "slices") of specific areas of a scanned object, allowing the user to see inside the object without actually cutting through [11,12].

Digital geometry processing is used to further generate a three-dimensional volume of the inside of the object from a large series of two-dimensional radiographic images taken around a single axis of rotation [13] which are used for diagnostic and therapeutic purposes in various medical disciplines.

Thus, this study is therefore carried out to evaluate the position and branching pattern of aortic arch in some South-South States in Nigeria using computed tomography scan.

Methodology

Site of study

The present study was carried out in some Southern Nigerian States including Cross River, Delta, Bayelsa, Akwa-Ibom and Edo States.

Study population

The study population consisted of patients of both genders, aged 18 years and above referred for chest CT scan within centres with CT-scan machine in South-South Nigeria. Their images obtained from their database were reviewed and analysed accordingly. Being retrospective, the need for informed consent was waived and the ethical clearance approved by the state ministry of health committee was sufficient.

Ethical clearance

Ethical clearance was obtained from Cross River State ministry of Health Calabar, with reference number: CRSMOH/RP/REC/2018/902. The institutional diagnostic centers requirements and guidelines were met.

Sampling Techniques

Tomographs corresponding to the sample size of 200 subjects were collected and carefully observed and analysed with the variations noted within the computer. Some tomographs were discarded using the exclusion criteria.

Study Design

A retrospective study of 200 apparently normal CT images of the chest of subjects acquired from the CT scanner was used, with the different variants noted. Image obtained were analysed by the radiologist as DICOM files and adequately representing both genders. This study lasted for a period of six (6) months only.

Exclusion criteria

Paediatric cases aged ≤17 years were excluded from the study. CT images (tomographs) with request forms or reports indicating conditions such as aneurysms, aortitis, aortic coarctation, aortic stenosis, atherosclerosis, Ehlers-danlos syndrome, Marfan syndrome, Kyphosis, Scoliosis and Lordosis and so on, were not used. Cases with history of chest trauma were also excluded from the study. In addition, blurred and unclear computed tomography scans were excluded from the study.

Statistical analysis

Data obtained were reported as tables, and bar charts, frequencies and graphs. Data were expressed using the elements of descriptive statistics. Statistical tools such as the one-way Analysis of Variance (ANOVA) and post hoc (LSD) were used. In addition, correlation and linear regression analysis were used. Analysis of results and findings was done with the use of Statistical Package for Social Sciences (SPSS) version 20.

Results

There were 200 chest CT images of which males are 108 (54%) and females 92 (46%), making up 100% of the subjects. Their ages ranged from 18 to 70 years extending across both sexes.

Variation in Position

Normal positioning of aortic arch in male is 108 (100%) and females 92 (100%), making a total of 200 subjects. No abnormal positioning of the aortic arch was recorded in this study; all 200 subjects had their arch within the limits of the superior mediastinum.

Pattern	Male	Female	Total
Normal	108 [100.0%]	**92 (100.0%)**	**200 (100.0%)**
Abnormal	0 (0.0%)	0 (0.0%)	0 (0.0%)
Total	108 (100.0%)	92 (100.0%)	200 (100.0%)

Chi cal. = na

Table 1: Percentage distribution of aortic arch position among the study population

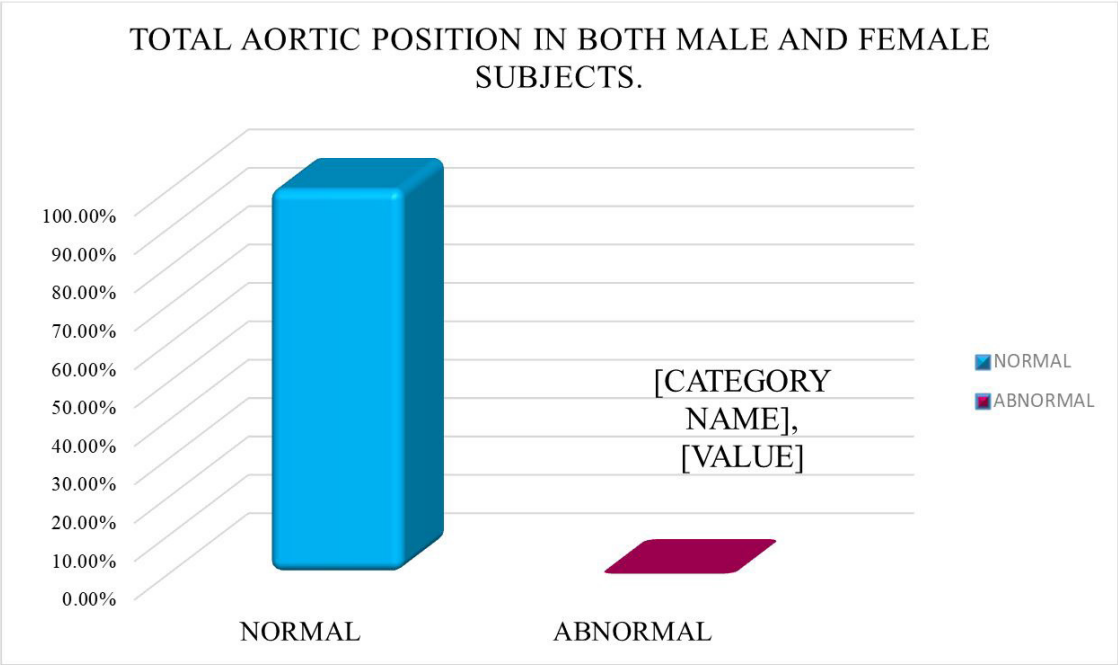

Figure 1: Total Aortic Position in both Male and Female Subjects

Variation in Branching Pattern

The frequency of aortic arch branching pattern among the population of study shows the normal pattern to be 104 (96.3%) in male subjects while female subject has 92 (100%) giving a total of 196 (98.0%).

Abnormal branching pattern in males is 4 (3.7%) while female subjects had no abnormal branching pattern culminating to a total of 4 abnormal branching patterns in the total study population (3.7%).

Pattern	Male	Female	Total
Normal	104 (96.3%)	92 (100.0%)	196 (98.0%)
Abnormal	4 (3.7%)	0 (0.0%)	4 (2.0%)
Total	108 (100.0%)	92 (100.0%)	200 (100.0%)

Chi cal. = 3.477; df = 1; p = 0.062 (NS)

Table 2: Percentages distribution of aortic arch branching pattern among the study population

The overall population N = 200 (male and female) showed that 196 (98%) had normal branching pattern which depicts a left sided aortic arch which with right brachiocephalic trunk, left common carorltid artery and left subclavian artery while 4 (2%) showed abnormal branching pattern where there are two with aberrant subclavian arteries and two with right sided arch. This makes the left subclavian and left common carotid arteries to be right sided as shown in figure 4 and 5.

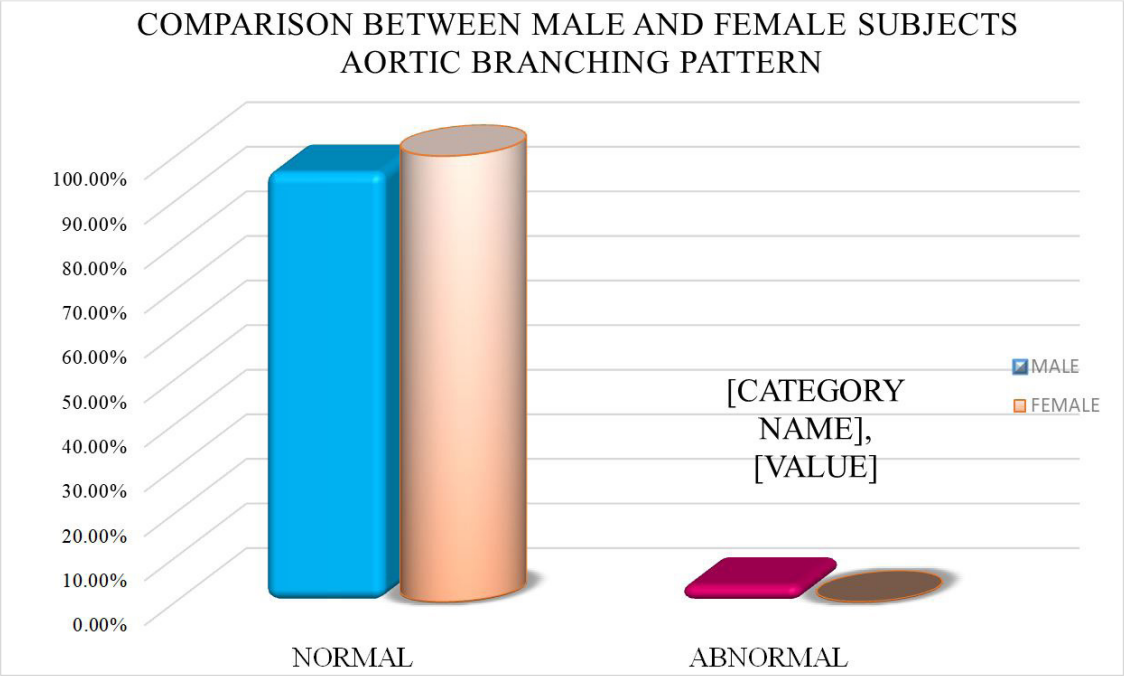

Figure 2: Comparison between Male and Female Subjects Aortic Branching Pattern

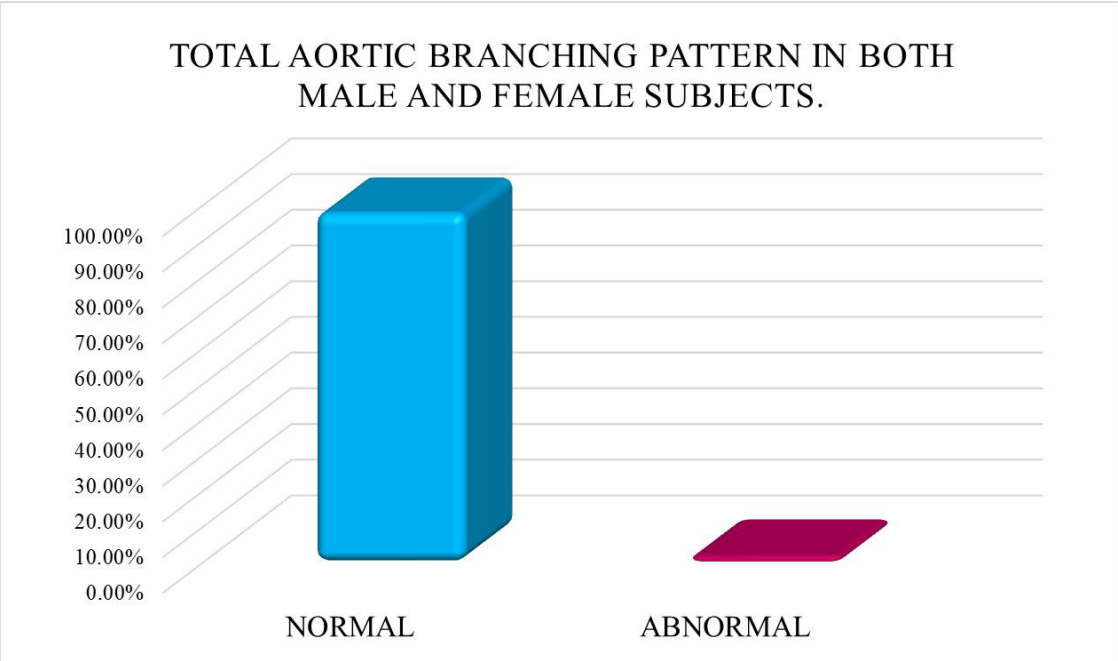

Figure 3: Total Aortic Branching Pattern in both Male and Female Subjects

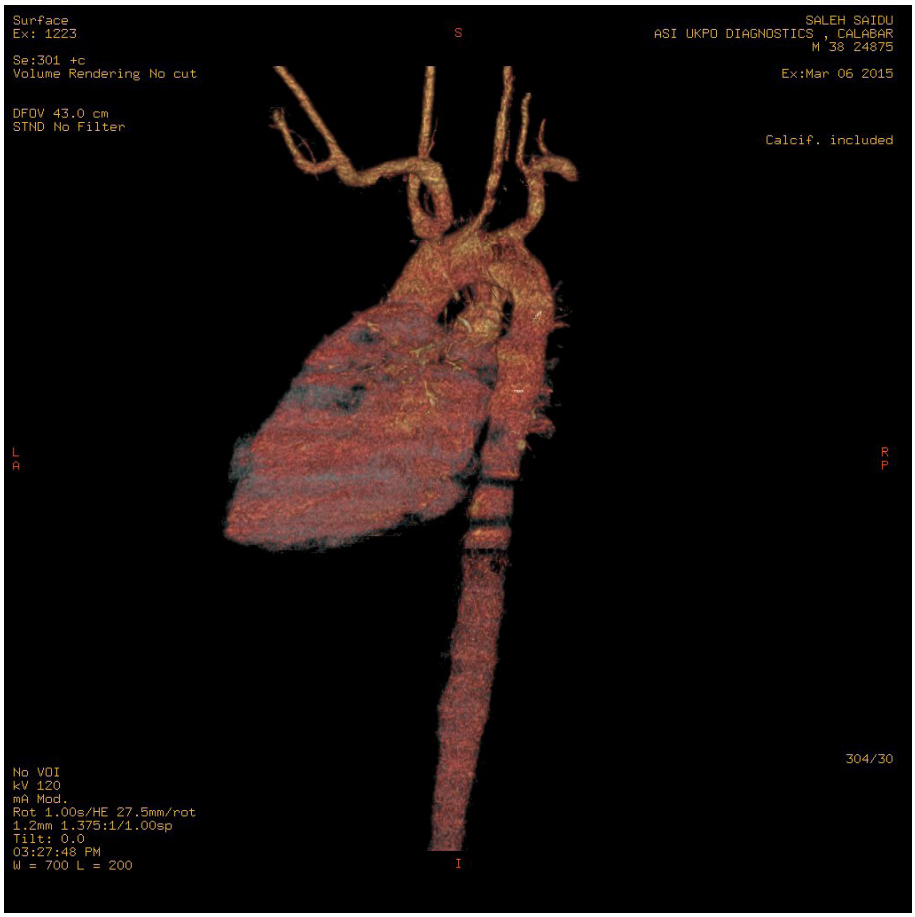

Figure 4: Showing specifically a right sided aortic arch and aberrant subclavian artery in a 3D reconstruction

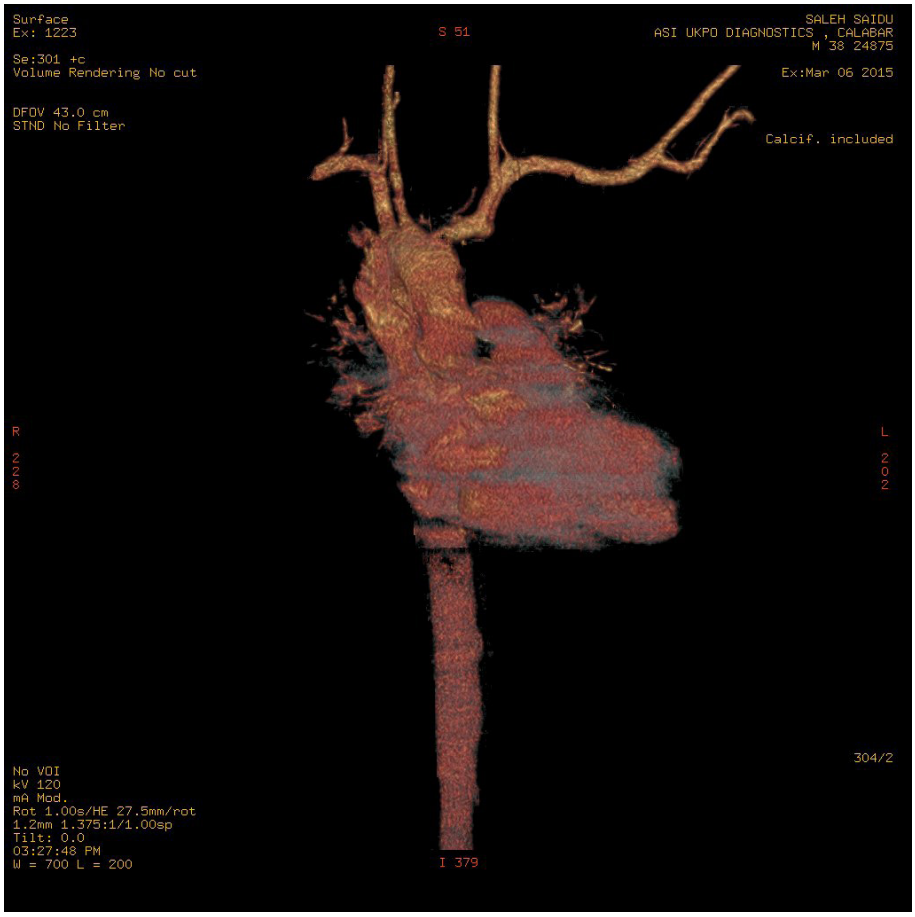

Figure 5: Showing a right sided aortic arch in a 3D reconstruction

Figure 6: Showing antero-posterior chest CT image of a right sided aortic arch showing, a respose right sided aortic arch normally called a Scout view or Preliminary view which is the 2D image usually used to plan the sliced axial Images

Discussion

This study assessed the anatomical variation in the position and branching pattern of aortic arch using computed tomography in some South-South States in Nigeria. Accurate anatomical knowledge of the arch of aorta and its major branches is of great importance in diagnostic and therapeutic procedures. Despite accurate preoperative assessment and adequate preparations, unavailability of detailed account of the aortic arch variations across different races can lead to unexpected complications which can be lethal if they occur during cardiovascular surgeries thereby causing life threatening problems. The position of aortic arch in all subjects appears to be constant (100%) in the superior mediastinum, slightly above the sternal angle. This corroborates a study by Shuford *et al.* [8] that stated that nineteen (19) cases have been previously reported in the world literature and their study collected additional six (6) cases with four located on the left side. There is however, no recent study delineating the cervical aortic arch. Cervical aortic arch was reportedly characterized by an aortic arch extending abnormally high in the neck occurring more commonly on the right was unsurprisingly absent in this study and till date, data presenting the possible variations has not been adequately unearthed in any study population. The distribution of aortic arch branching pattern among the study population, showed that out of the 200 subjects 98% presented with the classical branching pattern while only 2% showed variant branching pattern. All 2% presenting with the variant pattern were males. Right sided aortic arch appears to be three out of the four variant patterns while one appears as an aberrant subclavian artery. The percentage to population prevalence of variation is demonstrated in the results from a cadaveric study conducted by Rao *et al.,* [14] in Trinidadians on "branching pattern of arch of aorta with its embryological significance. Their study demonstrated an 8.3% variation in the branching pattern. Similarly, a cadaveric study by Alsaif *et al.* among the Nepali population showed a 25% variation [15]. More so, closely related is the work is another study by Satyapal *et al.* out of three hundred and twenty (320) aortic arch angiograms, a 5.3% [17] aortic arch branching pattern variations were observed also among the Nepalese [16]. A variation if clinically silent and not recognized may have fatal consequences during trauma, this supports the significance of this study. Interestingly, Voster et al [17] opined that a variation such as a common trunk for Brachiocephalic trunk (BCT) and Left common carotid artery (LCCA) may actually be useful clinically during catheterization

of LCCA which originates from BCT as there is no need of catheter exchange [17]. Congenital anomalies of aortic arch leading to variations in branching pattern occur with about equal frequency in both sexes with or without racial prevalence [3]. This is however contrary to the findings of this research which shows prevalence in males than females. In another cadaveric study from different populations by Virendra *et al.*, on the "Anatomical variations in the branching pattern of the aortic arch" in India, demonstrated a 36.5% of the variant branching patterns [17]. This is however, higher compared to other studies. The inconsistency of variation predominance suggests the role of racial differences as demonstrated in the South African population in which 5.3% (out of 320) variation most similar to the result of this research of which 200 specimens presented 2% variation.

Conclusively, no variation was noticed in the position of aortic arch in this study in both male and female subjects. However, there is a 2% variation in the branching pattern of aortic arch with right sided arch being predominant. Males have all 2% variant while females show no variant branching pattern of their aortic arch.

References

1. Drake RL, Vogl AW, Mitchell AW (2015) Gray's anatomy for students, 3rd edn Philadelphia. PA: Churchill Livingstone Elsevier.

2. Ellis H (1964) Clinical anatomy: a revision and applied anatomy for clinical students. Annals of Surgery. 1: 31-5.

3. McElhinney DB, Goldmuntz E (2004) Abnormalities of the aortic arch. Orphanet encyclopedia 1-3.

4. Momma K, Matsuoka R, Takao A (1999) Aortic arch anomalies associated with chromosome 22q11 deletion (CATCH 22). Pediatr cardio 20: 97-102.

5. Nayak SR, Pai MM, Prabhu LV, D'Costa S, Shetty P (2006) Anatomical organization of aortic arch variations in the India: embryological basis and review. J Vascular Brasileiro 5: 95-100.

6. Acar M, Ulusoy M, Zararsiz I, Efe D (2013) Anatomical variations in the branching of human aortic arch. Biomed Res

7. Vucurevic G, Marinkovic S, Puskas L, Kovacevic I, Tanaskovic S, et al. (2013) Anatomy and radiology of the variations of aortic arch branches in 1,266 patients. Folia morphologica 2: 113-22.

8. Shuford WH, Sybers RG, Milledge RD, Brinsfield D (1972) The cervical aortic arch. Am J Roentgenol Radium Ther Nucl Med 116: 519-27.

9. McElhinney DB, Tworetzky W, Hanley FL, Rudolph AM (1999) Congenital obstructive lesions of the right aortic arch. The Annals of thoracic surgery 67(4): 1194-202.

10. Harley HR (1959) The development and anomalies of the aortic arch and its branches. With the report of a case of right cervical aortic arch and intrathoracic vascular ring. Br J Surgery 46: 561-73.

11. Merriam-Webster "computed tomography – Definition from the Merriam-Webster Online Dictionary".

12. Natsis KI, Tsitouridis IA, Didagelos MV, Fillipidis AA, Vlasis KG, Tsikaras PD (2009) Anatomical variations in the branches of the human aortic arch in 633 angiographies: clinical significance and literature review. Surgical and radiologic anatomy. 31: 319-23.

13. Herman GT (2009) Fundamentals of computerized tomography: image reconstruction from projections. Springer Science & Business Media

14. Rao NS, Meera K, Sujatha K, Rao HK (2017) A Study On Branching Pattern Of Arch Of Aorta With Its Embryological Significance And Review Of Literature. Int J Anat Res 5: 3516-20.

15. Alsaif HA, Ramadan W (2010) An anatomical study of the aortic arch variations. Med Sci 17: 1.

16. Satyapal KS, Singaram S, Partab P, Kalideen JM, Robbs JV (2003) Aortic arch branch variations--case report and arteriographic analysis. South African journal of surgery. Suid-Afrikaanse tydskrif vir chirurgie 41: 48-50.

17. Patil ST, Meshram MM, Kamdi NY, Kasote AP, Parchand MP. Study on branching pattern of aortic arch in India. Anatomy & cell biology 45: 203.

18. Virendra B, Rakhi R, Vaishali J, Vishal B, Shiv R (2013) Anatomical variation in the branching of human aortic arch; a cadaveric study from Central India. *ISRN Anatomy* ID828969.