Open Access

SCHOLARENA

SAJ Pharmacy and Pharmacology

RESEARCH ARTICLE

ISSN: 2375-2262

Vaccination Site Tumors in Human Beings

Sunita Dinkar[1*], Srajan Dashore[2], Foram Modh[1] and Shailesh Patel[3]

[1]*Department of General Surgery, Banas Medical College and Research Institute, Palanpur, Gujarat, India*
[2]*Department of Radiology, Banas Medical College and Research Institute, Palanpur, Gujarat, India*
[3]*Shailesh Patel, Department of Pathology, Banas Medical College and Research Institute, Palanpur, Gujarat, India*

[*]**Corresponding author:** Sunita Dinkar, Department of General Surgery, Banas Medical College and Research Institute, Palanpur, Gujarat, India, Tel: +91-9099018120; E-mail: dinkarsunita70@gmail.com

Citation: Sunita Dinkar, Srajan Dashore, Foram Modh, Shailesh Patel (2020) Vaccination Site Tumors in Human Beings. SAJ Pharma Pharmacol 6: 109

Abstract

Neoplasms following vaccination at the site of injection have not been reported in human beings. Sarcomas, chiefly fibrosarcomas have been reported in cats associated mainly with Rabies and FeLV vaccines. We report a case of fibrolipoma following vaccination at the site of injection in a 4 year old child, which was successfully removed enmass and has not showed any signs of recurrence over a period of follow up of 10 months. Our aim to publish this case is to highlight occurrence of neoplasms following vaccination in human beings and increase the awareness regarding the same.

Participants A: 4 years old child

Main Outcome Measures: Consequences for postoperative morbidity were evaluated.

Results: Good result with no recurrence after 10 month of follow up.

Conclusions: There is a possibility of developing neoplasms following vaccination at the site of injection. Increasing awareness regarding this will help to recognize more such cases and help in reviewing the possible mechanism of such neoplasms and preventing such adverse events.

Keywords: Neoplasms; Fibrosarcoma; Osteosarcoma; Lipomyoma; Femur Bone; Tumor; Herpesvirus; Panleukopenia; Calicivirus

Introduction

Neoplasms at injection site following vaccination have not been reported in human beings; though virus associated neoplasms have been reported. Sarcomas, mostly fibrosarcoma have been reported in cats and dogs at injection site following Rabies and FeLV vaccination [1-4]. Grasso and Golberg demonstrated the induction of sarcomas in rats after the subcutaneous injection of certain food colourings [5]. In human beings there have been cases of various sarcomas including osteosarcoma, Ewing's sarcoma, and angiosarcoma associated with prostheses and vascular grafts [6,7]. Cancers including angiosarcomas have been reported in human beings at the sites of shrapnel injuries where fragments have remained for several years [5,6].

Methodology

A 4year old child presented with complaint of huge swelling of 15cmx7cmx5cm (L x W x H) occupying medial side of almost 3/4th of left thigh. The swelling was noticed 6months after vaccination for Measles (MR Vaccine) which gradually increased in size over 2 years but increasing rapidly in size for last 2 months. Local examination revealed huge swelling of 15cmx7cmx5cm occupying medial side of almost 3/4th of left thigh. No vascular engorgement, pulsation or change in colour could be seen on the overlying skin. On palpation swelling was noted to be firm in consistency of same size with no palpable pulsation. Routine blood investigations and chest X-ray were normal. CT Scan showed probability of lipomyoma with muscles stretched out in anterior aspect (Figure 1). Swelling was in direct contact with bone. Blood vessels could be seen on medial aspect free from the tumor.

Patient was taken for surgery. Incision was kept vertically along the longitudinal axis of swelling. Tumor could be seen immediately beneath subcutaneous tissue. To fecilititate complete removal and to get all the boundaries clear from the surroundings vascular structures were safeguarded. Femoral vessels were identified and looped. In contradiction to CT findings femoral vessels were on lateral aspect of the tumor (Figure 2). It looks like vessels seen on CT on medial side were profunda branches of Left Femoral artery and vein and Superficial artery and were not seen on CT due to stretching out. Tumor could be seen to be encased between left superficial femoral vessels on lateral aspect and profunda branches and other branches on medial aspect. Medial branches after arising from Left superficial femoral vessels traversed medially and then posteriorly behind the tumor again traversing laterally thus forming a loop around the tumor.

Tumor was in direct apposition to femur bone through its longitudinal extent. Inspection was done to see if there was any indentation into the femur or any signs of involvement of the femur. After reassuring that the boundries of the tumor were not entering into any neighboring structures, tumor was carefully separated from the surrounding structures, namely femur posteriorly, pubis superiorly and muscles and vessels laterally and medially. Tumor was removed in toto (Figure 3). While doing so there was injury to a big branch of left femoral vein on the medial side as it was stretched out over the tumor. Distal end of the vein was tied and proximal end which had avulsed just flush to the left femoral vein was repaired with 5-0 prolene continuous stitch in two layers. Hemostasis was achieved. Wash was given with saline and betadine. Drain put below muscle layer and brought out through skin. Closure was done in layers.

Results

There were no post-operative complications. There was no limb oedema post-operatively. Wound healed by primary intention. Stitches were removed on 10th post-op day. Follow up of patient taken after 10 months does not show recurrence.

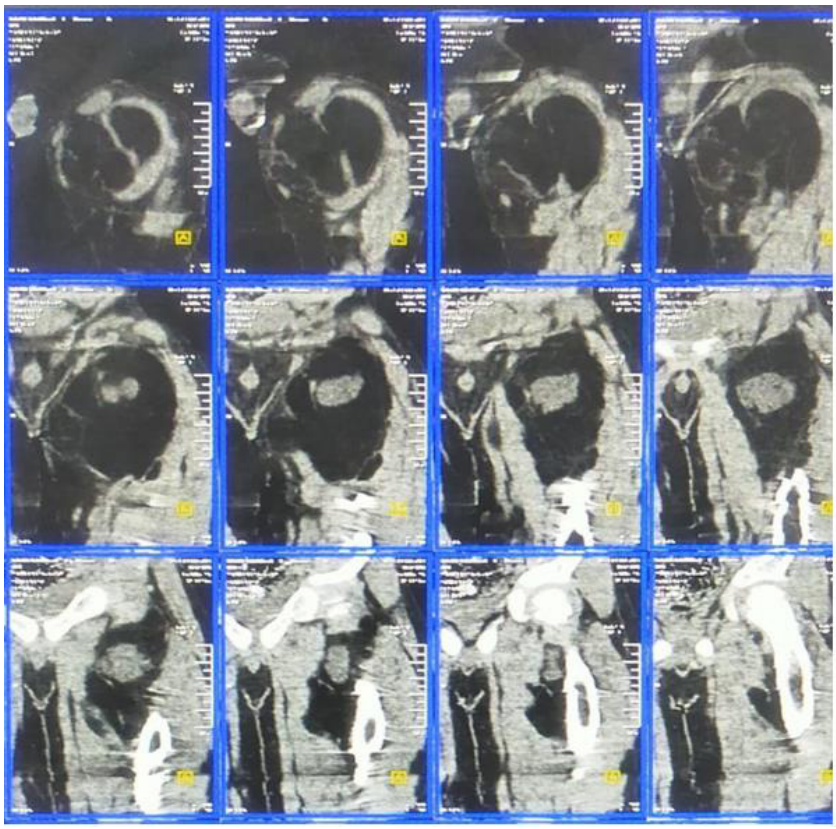

Figure 1: CT Scan showing Extent of the tumor

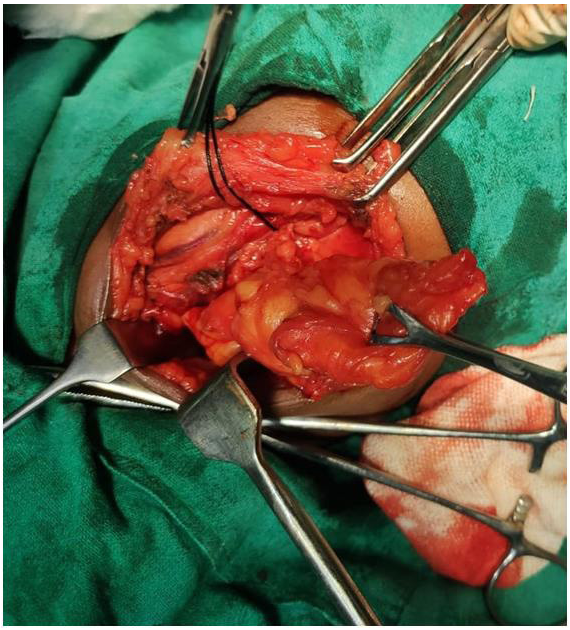

Figure 2: Excision of tumor: Femoral Vessels looped separately

Figure 3: Fibrolipoma after removal

Discussion

Though mostly seen following Rabies and FeLV vaccination injection site in cats and dogs, sarcomas have been reported after herpesvirus, panleukopenia and calicivirus vaccination also [1-4]. In cats vaccine injection site sarcomas have been reported more in young cats as compared to non-vaccine site sarcomas with chronic inflammation considered as the possible mechanism [8]. They have been associated with an inflammatory infiltrate, primarily macrophages, that are frequently reported to contain bluish foreign material and may include giant cells [9,10]. Most of the studies related to vaccine associated sarcomas have been done in cats. Possible mechanisms of induction of sarcomas in Cats have been attributed to adjuvants, inflammatory process [5,8,11]. Reactions were most common with aluminum adjuvant vaccines, Although less common with non-aluminum adjuvant vaccines, and not seen with nonadjuvant vaccines, the size of the reaction was not related to the presence of aluminium [11].

In human beings Reactogenicity of vaccines has also been studied but its role in inducing tumors has not been stated [12]. Some of the studies could not find association of either increase or decrease the risk of vaccine-associated sarcoma formation in cats with specific brands or types of vaccine within antigen class, vaccine practices such as reuse of syringes, concomitant viral infection, history of trauma, or residence [13,14]. Though possibility of association with temperature at the time of injection could not be ruled out. Administration of cold vaccines was associated with a higher risk of sarcoma development than was administration of room temperature vaccines, with ORs ranging from 2.04 (95% CI, 1.27 to 3.28) to 2.05 (95% CI, 1.20 to 3.54) [13]. There was evidence to suggest that certain long-acting injectable medications may also be associated with sarcoma formation [13]. The mainstay of treatment for sarcomas in animals has been shown to be surgery and radiotherapy for prevention of recurrence with limited role of chemotherapy [15-18].

The size of the tumor in this child was so large for the age and weight of the child that our first clinical impression was sarcoma but fortunately it turned out to be fibrolipoma. There is no recurrence till last follow-up. It is important to elicit clinical history of vaccination for swellings seen in pediatric age group.

Clinical Implications and Current Practice in Human Beings

Injection safety and other basic infection control practices are central for protecting against risk of infectious and non-infectious adverse events. CDC is collaborating with the Safe Injection Practices Coalition (SIPC) to develop and implement an educational campaign to promote safe injection practices. Health workers or local vaccinators are trained to store and handle vaccines properly, reconstitute, administer correctly, and have the right equipment and materials. Evaluation of the injection site is done before administering vaccine. Vaccinators should use appropriate needle length and gauge adjusted for age, body mass and injection site. Vaccinators are trained not to aspirate during Intramuscular injections, not to stimulate the injection site by rubbing or pitching and not to warm vaccine prior to injection.

While most vaccine adverse reactions are minor and self-limited lasting from one to few days, some vaccines have been associated with extremely rare but serious health effects. Monitoring for vaccine-associated adverse events is essential. CDC and the FDA use four main systems to monitor the safety of vaccines in use: the Vaccine Adverse Event Reporting System (VAERS), the Vaccine Safety Datalink (VSD), the Clinical Immunization Safety Assessment (CISA) project, and the Postlicensure Rapid Immunization Safety Monitoring System (PRISM). CIOMS/WHO Working Group on Vaccine pharmacovigilance aims to detect adverse events early to trigger accurate risk assessment and appropriate response (risk-management) to the problem.

FDA's PRISM uses a computer algorithm to conduct active vaccine safety surveillance. This helps in identifying rare adverse reactions, risk factors/preexisting conditions associated with a higher incidence of adverse reactions. It also helps in identifying particular vaccine lots with unusually high rates or certain types of events. It also identifies possible adverse reactions that might warrant

further study to establish the association of an adverse event with vaccination or affect current immunization recommendations. AEFI (Adverse Reaction following immunization) surveillance in India is followed for reporting adverse events to be filled in by the medical personnel as per VAERS table. After vaccination there is no door to door active surveillance asking for adverse events. Medical personnel educate the parents to contact them in case of adverse event. Health workers also visit door to door regularly who can be informed about any adverse events.

Key Messages

- Neoplasms specially Fibrosarcomas are known to occur in cats and have been reported to be increasing in incidence in recent decade with an incidence of ranging from 10 cats per 1,00,000 to 130 cases per 1,00,00.
- Vaccine associated neoplasms in human beings have not been reported in literature. It seems that such cases in human beings are either rare or under reported.
- Awareness regarding occurrence of neoplasms following vaccination at injection site will help in reporting of such incidences. If more cases are reported then possible mechanism of occurrence can be identified whether it is the vaccine responsible, temperature of vaccine at the time of administration or the technique of injecting.
- Continuous vaccine pharmacovigilance and evaluation of risks and benefits of vaccines is required and results of these need to be communicated broadly to identify emerging adverse events following vaccination and address them at the earliest to strengthen the confidence in immunisation programmes [19].

Acknowledgments

We are very grateful to staff of Banas Medical College and Research Institute, Palanpur, Gujarat, India.

References

1. Doddy FD, Glickman LT, Glickman NW, Janovitz EB (1996) Feline fibrosarcomas at vaccination sites and non-vaccination sites. J Comp Pathol 114: 165-74.

2. Kass PH, Barnes Jr WG, Spangler WL, Chomel BB, Culbertson MR (1993) Epidemiologic evidence for a causal relation between vaccination and fibrosarcoma tumorigenesis in cats. J Am Vet Med Assoc 203: 396-405.

3. Hendrick MJ, Shofer FS, Goldschmidt MH, Haviland JC, Schelling SH, et al. (1994) Comparison of fibrosarcomas that developed at vaccination sites and at non-vaccination sites in cats: 239 cases (1991-1992). J Am Vet Med Assoc 205: 1425-9.

4. Terry M Jacobs, Cathy E Poehlmann, Matti Kiupel (2017) Injection-Site Sarcoma in a Dog: Clinical and Pathological Findings. Case Rep in Vet Med.

5. Kevin N. Woodward (2011) Origins of Injection-Site Sarcomas in Cats: The Possible Role of Chronic Inflammation—A Review. International Scholarly Research Network ISRN Veterinary Science.

6. T Teltzrow, C Hallermann, S Muller, V Schwipper (2006) Foreign body-induced angiosarcoma 60 years after a shellsplinter injury. Mund Kiefer Gesichtschir 10: 415-18.

7. O Ben-Izhak, E Vlodavsky, A Ofer, A Engel, S Nitecky, et al. (1999) Epithelioid angiosarcoma associated with a Dacron vascular graft. Am J Sur Pathol 23: 1418-22.

8. Gregory K Ogilvie, DVM, DACVIM (Internal Medicine, Oncology) (2004) Injection Site and Vaccine Associated Sarcomas: New Advances for a New Millennium. Speech at World Small Animal Veterinary Association World Congress Proceedings.

9. Hendrick MJ, Brooks JJ (1994) Postvaccinal sarcomas in the cat: Histology and immunohistochemistry. Vet Pathol 31: 126-9.

10. Esplin DG, McGill LD, Meininger AC, Wilson SR (1993) Postvaccination sarcomas in cats. J Am Vet Med Assoc 202: 1245-7.

11. Lester S, Clemett T, Burt A (1996) Vaccine site-associated sarcomas in cats: Clinical experience and a laboratory review (1982-1993). J Am Anim Hosp Assoc 32: 91-5.

12. Caroline Herve, Beatrice Laupeze, Giuseppe Del Giudice, Arnaud M Didierlaurent, Fernanda Tavares Da Silva (2019) The how's and what's of vaccine reactogenicity. npj Vaccines 4: 39.

13. Philip H. Kass, Spangler WL, Hendrick MJ, McGill LD, Esplin DG, et al. (2003) Multicenter case-control study of risk factors associated with development of vaccine-associated sarcomas in cats. J Am Vet Med Assoc 223: 1283-92.

14. Gobar GM, Kass PH (2002) World Wide Web-based survey of vaccination practices, postvaccinal reactions, and vaccine site-associated sarcomas in cats. J Am Vet Med Assoc 220: 1477-82.

15. Burton G, Mason KV (1997) Do postvaccinal sarcomas occur in Australian cats?. Aust Vet J 75: 102-6.

16. Macy DW (1999) Current understanding of vaccination site-associated sarcomas in the cat. J Feline Med Surg 1: 15-21.

17. Gagnon AC (2000) Drug injection-associated fibrosarcoma in a cat. Feline Pract 28: 18-21.

18. Esplin DG, Bigelow M, McGill LD, Wilson SR (1999) Fibrosarcoma at the site of a lufenuron injection in a cat. Vet Cancer Soc Newsl 23: 8-9.

19. Heininger U (2009) A risk-benefit analysis of vaccination. Vaccine 27: G9-12.