

CASE REPORT

Traumatic Dissection and Thrombosis of the Mid Renal Artery with Endovascular Repair and Review of the Literature

Smith R¹, Harding J¹, Rzucidlo EM² and Piccolo C^{2*}

¹Edward Via College of Osteopathic Medicine Carolinas, Spartanburg, United States

²McLeod Regional Medical Center, Florence, United States

***Corresponding author:** Piccolo C, McLeod Regional Medical Center, Florence, SC 29506, United States, E-mail: carmenpiccolo@gmail.com

Citation: Smith R, Harding J, Rzucidlo EM, Piccolo C (2018) Traumatic Dissection and Thrombosis of the Mid Renal Artery with Endovascular Repair and Review of the Literature. J Angiol Circulat Sys 1: 101

Abstract

We report a case of a 48-year old male status post motor vehicle accident who was found to have a left renal artery dissection (RAD) and thrombosis that underwent endovascular repair with a Viabahn stent and his 1 year follow up. The limited available literature on the treatment of traumatic renal artery dissections and occlusions is then reviewed. We then demonstrate that endovascular repair of traumatic renal artery dissection is possible in patients with a complete ischemic time less than 3 hours and no need for laparotomy.

Keywords: Traumatic renal artery dissection; Renal artery stent graft repair

Introduction

Overall, renal artery dissection (RAD) is categorized into two main subsets: underlying renovascular diseases (ex: FMD) and mechanical, (ex: trauma, iatrogenic) [1]. Traumatic renal artery injury is rare with only 11 patients having a blunt traumatic renal artery dissection (RAD) reported in the literature. Renal artery injury in blunt trauma has an incidence of 0.05% [2]. Typically, there are other significant concomitant renal findings when the renal artery is injured [2]. Only 17% of patients have an isolated renal artery injury as the only intra-abdominal trauma [2]. In general, the left renal artery is most commonly injured [3]. Two different mechanisms have been proposed [4,5]. The first is the left renal artery has more maximum angulation causing more traction force due to its' shorter length. Second is that it has more mobility which leads to more torsion at its' origin [4,5].

Treatment for traumatic RAD are through recommendations from small single-center studies with no large meta-analysis identifying a treatment consensus [6]. Bittenbinder, *et al.* has generalized the treatment into three options: open repair, embolization or endovascular repair [7]. In addition, conservative, non-interventional treatment has been advocated due to the historically poor technical results and high risk of thrombosis postoperatively [7-9].

Open repairs range from small laceration repairs to partial and total nephrectomies [7]. Three hours of complete ischemia or 6 hours of partial ischemia can lead to poor renal function, therefore there has been a significant emphasis on conservative treatment with follow up. In fact, 64% of patients undergoing open surgery end up with nephrectomy. For those having renal repair only 25% have renal preservation [7]. Larger case reviews have shown only 26% of patients with excellent technical repair regaining renal function, however 11% of those patients may still need delayed nephrectomy for refractory hypertension [7].

It is because of these poor long-term outcomes that leaders in trauma such as Feliciano have stated that no revascularization should be attempted if there is a functioning contralateral kidney [8]. Studies evaluating patients who had no attempt at revascularization have shown 57% of patients in follow up remain asymptomatic and normotensive [8].

To date, there is no consensus in the literature for endovascular treatment [7,8]. Even in 2013, endovascular stenting in renal trauma was reported as rare [7]. All literature on the topic is from small retrospective studies and case reports. Even in the patients treated with endovascular revascularization by stenting, there is no consensus in the type of stent to use. In a more recent case series, three different types of stents were used in 5 patients; 2 stent grafts, 2 non-covered balloon-expandable stents and 1 non-covered self-expandable tapered stent [7]. The long-term follow up in these patients was poor and there seemed to be no significant difference in renal salvage.

Case Report

This 48-year-old male patient presented to the emergency room 2 hours status post severe motor vehicle accident. Past medical history revealed no medical comorbidities or daily medications.

A CT displayed no perfusion to the left kidney with dissection (Figure 1). Secondary trauma survey identified left tibia-fibular fracture, small pneumothorax, mesenteric contusion and a concussion. The decision was made that he could benefit from an attempt at emergent endovascular revascularization given the early window of ischemia.

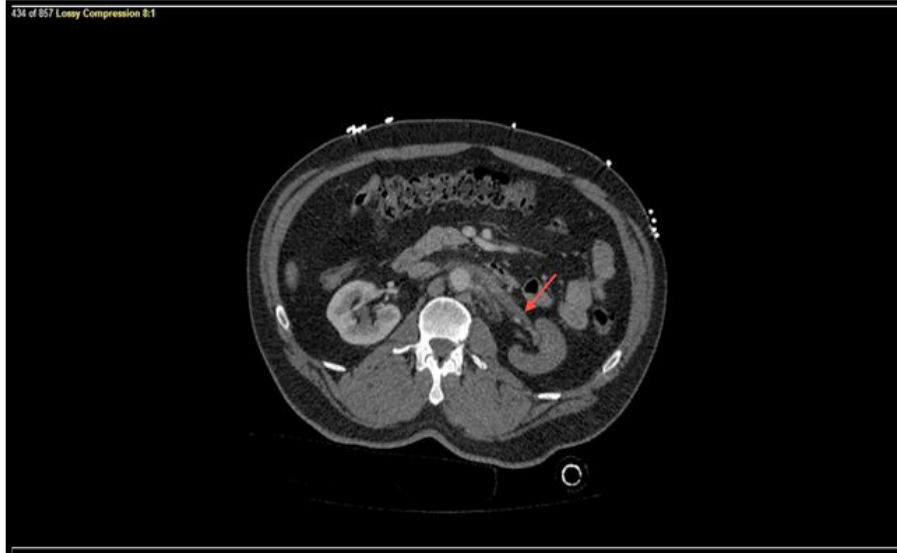


Figure 1: CT of Left Renal Artery Dissection and Thrombosis at initial presentation

The patient was emergently taken to the hybrid operating room and under local anesthesia right femoral access was obtained approximately 150 minutes after the injury. He was given 2500 units of heparin intravenously and kept subtherapeutic due to his high risk for concomitant bleeding secondary to mesenteric contusion. A 6F 45cm Destination sheath (Terumo) was placed below the renal arteries. An angled guide catheter (Cook) was placed through the sheath. The origin of the renal artery was engaged with a 0.35 Navicross catheter (Terumo). Crossing this lesion was technically difficult. However, using a V18 wire (Boston Scientific), a 0.14 Fathom wire (Boston Scientific) and a 0.18 Rubicon catheter (Boston Scientific) the lesion could be crossed. An angiogram was performed distally confirming true lumen with no extravasation. A 0.14 Platinum Plus wire (Boston Scientific) was positioned distally, and the tip of the wire stabilized under fluoroscopy. A 7 mm by 5 cm Viabahn graft (Gore) was deployed, with the sizing based off diameter measurements of the contralateral renal artery on the preoperative CT scan. Completion angiogram showed a patent stent with excellent nephrogram (Figure 2). The patient was discharged from the hospital on 81 mg of aspirin daily. During his hospitalization his urinary output remained normal, with normal blood pressure, and an admission creatinine 1.2 mg/dl with a discharge level of 0.8 mg/dl. The patient's GFR was 71 on admission and was 75 on his 12-month follow up (Figure 3).

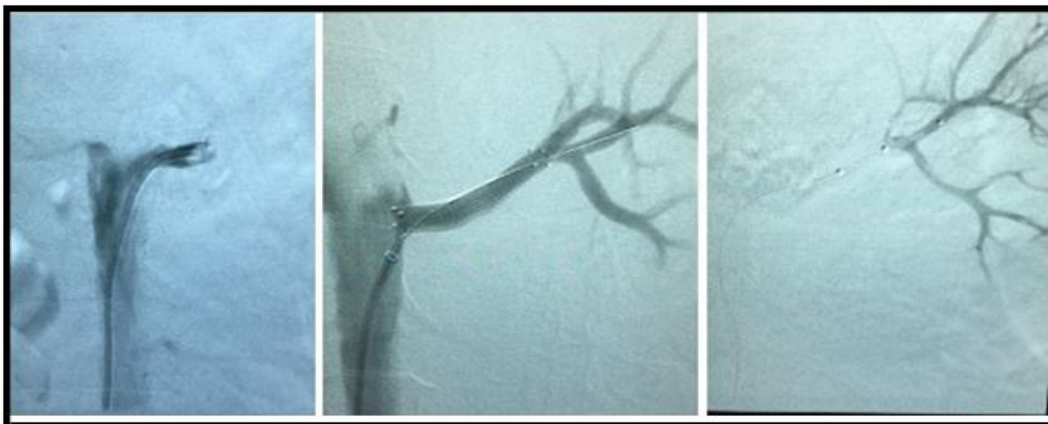


Figure 2: Intra-operative angiogram showing zero perfusion to the left kidney, Viabahn stent placement, and reperfusion of left kidney

Follow up duplex ultrasonography at 1, 3, 6 and 12 months demonstrated patency of the stent graft with normal peak systolic velocities, renal aortic ratios (RAR), kidney size and resistive indexes. At the 12 month duplex the kidney measured 10.31cm by 4.7cm and the resistive index was noted to be 0.69 and a RAR of 1.2. On his 12-month visit the patient was normotensive and not requiring any anti-hypertensive medication. Anti-platelet therapy is planned to be continued lifelong.

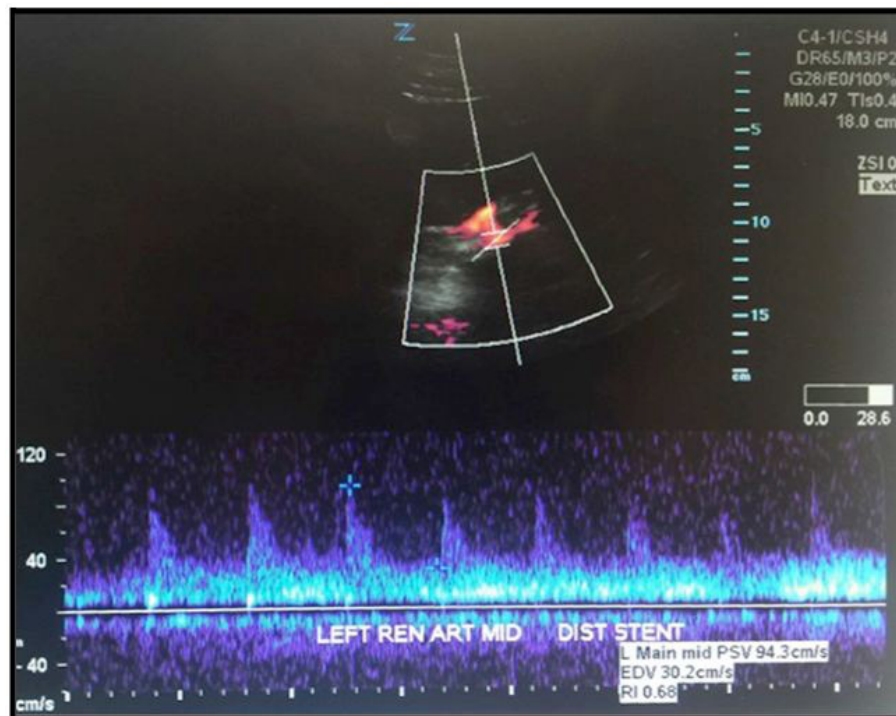


Figure 3: 2 month follow up duplex ultrasonography status post stent graft repair

Discussion

Although each treatment modality has its considerations, endovascular repair is reserved for patients that have renal artery injury with a complete ischemic window less than 3 hours [8]. Although there are no meta-analysis to prove these claims, individual cases in the setting of trauma have shown that endovascular stenting of the renal artery has better long term outcomes, making endovascular stenting the primary choice for traumatic RAD [9]. Open repair could be indicated over endovascular stenting in certain cases, such as a patient with unstable vital signs concerning for hemorrhage, kidney ischemia time greater than 4 hours, or any concomitant visceral organ damage requiring a laparotomy [10]. There is no literature that has any long-term outcomes either in patients treated with either open or endovascular revascularization.

Postoperative complications seen after endovascular repair of traumatic RAD include occlusion or stenosis of the stent graft, atrophy of the kidney, and malignant hypertension. Lopera and associates found that of the 6 patients with endovascular repair only 2 were found to have primary patency and of those only one was followed for greater than 24 months. However, Chabrot and associates followed 3 patients after endovascular repair ranging from 23 to 30 months [11]. Of those 3 patients, all had successful long-term outcomes with one requiring an additional endovascular procedure for primary assisted patency at 3 months. In that paper, specific targets that were identified for long-term success were creatinine, blood pressure, and CTA patency.

Short-term postoperative surveillance involved duplex ultrasonography. Although these conditions can occur, we have demonstrated an uncomplicated intermediate-term follow up of an endovascularly repaired traumatic RAD supporting the treatment of this patient with stent graft repair [12-15]. We suggest the use of covered stent grafts given the traumatic nature and the potential risk of extravasation. Prior studies have shown that with extravasation, renal artery salvage is not possible and therefore embolization was required [7]. While embolization may be possible for unstable patient's, the risk for other concomitant intra-abdominal injuries in these patients is high and usually require open repair. In addition, with embolization there is still high risk for back bleeding from the kidney (if the entire lesion cannot be isolated) and long-term complications from the renal ischemia. In all the available literature there has been no consensus on long-term medical therapy with most papers failing to mention if any medical treatment has been used. We have chosen to keep the patient on aspirin, 81mg daily.

Conclusion

This case report highlights the uniqueness as well as the successful treatment of a left renal artery dissection and thrombosis in a patient with multiple traumatic comorbidities via an endovascular stent. Due to the low incidence of blunt traumatic renal artery dissection and thrombosis, there are no general treatment guidelines. With the positive outcome in this case and based on our review of the literature, we suggest that timely endovascular treatment with stent graft repair is a viable option for traumatic renal artery dissection, especially when able to be performed early in the ischemic window.

References

1. Ando T, Ohno H, Hirata Y, Emoto A, Ogata S, et al. (2005) Spontaneous Recovery From Renal Infarction Resulting From Renal Artery Dissection. *Intern J Urol* 12: 405-8.
2. Sangthong B, Demetriades D, Martin M, Salim A, Brown C, et al. (2006) Management And Hospital Outcomes Of Blunt Renal Artery Injuries: Analysis Of 517 Patients From The National Trauma Data Bank. *J Am Coll Surg* 203: 612-7.
3. Letsou GV, Gusberg R (1990) Isolated Bilateral Renal Artery Thrombosis: An Unusual Consequence Of Blunt Abdominal Trauma-Case Report. *J Trauma* 30: 509-11.
4. Nakayama T, Okaneya T, Kinebuchi Y, Murata Y, Iizuka K (2006) Thrombolytic Therapy For Traumatic Unilateral Renal Artery Thrombosis. *Int J Urol* 13: 168-70.
5. Evans A, Mogg RA (1970) Renal Artery Thrombosis Due To Closed Trauma. *Trans Am Assoc Genitourin Surg* 62: 40-6.
6. Elliott SP, Olweny EO, Mcaninch JW (2007) Renal Arterial Injuries: A Single Center Analysis Of Management Strategies And Outcomes. *J Urol* 178: 2451-5.
7. Bittenbender E, Reed A (2013) Advances In Renal Intervention For Trauma. *Seminars In Vascular Surgery* 26: 165-9.
8. Heldenberg E, Bass A (2013) Blunt Renal Artery Trauma: How Should It Be Treated Or Rather, Should It Be Treated? *Isr Med Assoc J* 15: 311-2.
9. Lee U, White R (2002) Endovascular Management of Blunt Traumatic Renal Artery Dissection. *J Endovasc Ther* 9: 354-8.
10. Long JA, Manel A, Penillon S, Badet L, Sessa C, et al. (2004) Traumatic Dissection Of The Renal Pedicle. Modalities of Management In Adults And Children. *Prog Urol* 14: 302-9.
11. Chabrot P, Cassagnes L, Alfidja A, Mballa JC, Nasser S, et al. (2010) Revascularization Of Traumatic Renal Artery Dissection By Endoluminal Stenting: Three Cases. *Acta Radiologica* 51: 21-6.
12. Memon S, Cheung BYK (2005) Long-Term Results of Blunt Traumatic Renal Artery Dissection Treated By Endovascular Stenting. *Cardiovasc Intervent Radiol* 28: 668-9.
13. Dowling JM, Lube MW, Smith CP, Andriole J (2007) Traumatic Renal Artery Occlusion In A Patient With A Solitary Kidney: Case Report Of Treatment With Endovascular Stent And Review Of The Literature. *Am Surg* 73: 351-3.
14. Flugsrud GB, Brekke M, Roise O (2005) Endovascular Stent in The Acute Treatment Of Blunt Renal Arterial Injury. *J Trauma* 59: 243-5.
15. Goodman DN, Saibil EA, Kodama (1998) RT Traumatic Intimal Tear of the Renal Artery Treated By Insertion of A Palmaz Stent. *Cardiovasc Intervent Radiol* 21: 60-72.