

# Management of Esophageal Denture Impaction Following an Epileptic Crisis: Report an Unusual Case

Hammouda Y<sup>1\*</sup>, Anas C<sup>2</sup>, Oukessou Y<sup>1</sup>, Rouadi S<sup>1</sup>, Abada RL<sup>1</sup>, Roubal M<sup>1</sup> and Mahtar M<sup>1</sup>

<sup>1</sup>Department of Otorhinolaryngology, Head and Neck Surgery Ibn Rochd Hospital, King Hassan II University, Casablanca, Morocco

<sup>2</sup>Department of Otorhinolaryngology, Head and Neck Surgery, King Hassan II University & Ibn Rochd Hospital, Morocco

\*Corresponding author: Hammouda Y, Department of Otorhinolaryngology, Head and Neck Surgery Ibn Rochd Hospital, King Hassan II University, Casablanca, Morocco, Tel: 0677610431, E-mail: yassir1ham@gmail.com

Citation: Hammouda Y, Anas C, Oukessou Y, Rouadi S, Abada RL, et al. (2021) Management of Esophageal Denture Impaction Following an Epileptic Crisis: Report an Unusual Case. SAJ Case Report 8: 101

## Abstract

**Introduction:** Impacted foreign bodies in the esophagus are common. In the esophagus, these are usually bones. The incidence of ingested dental prostheses is not highlighted in the literature, especially in patients treated for epilepsy, whose ingestion occurs after a convulsive seizure.

**Presentation of cases:** Here we report our patient who had been history of epilepsy, with dental prosthesis ingestion during an epileptic crisis, our case has benefited from a plain radiography demonstrated the denture which had radiolucent metal wires attached. Rigid esophagoscopy, detected the denture denture in the esophagus. The denture could not be removed endoscopically by rigid esophagoscopy, a transcervical esophagotomy was performed to removal of ingested denture.

**Discussion:** Diagnosis is based on history and examination, with most patients presenting with vomiting, and dysphagia. The plain cervico-Thoracic radiograph with pharyngoscopy and oesophagoscopy are the preferred test. The complication of denture ingestion is rare but can be severe, with esophageal perforation being the most common and feared. The traitement is based on endoscopic approach, the surgical management by oesophagotomy is indicated after trials of endoscopic approach had failed.

**Conclusion:** Dentures can be accidentally ingested. Denture loosening leads to accidental denture ingestion during an epileptic crisis. Patients with denture loosening should be recommended to visit dentist as soon as possible. Early diagnosis and treatment is vital in the management of swallowed denture.

**Keywords:** Denture Ingestion; Plain Radiography; Rigid Esophagoscopy; Transcervical Esophagotomy

## Introduction

Ingestion of foreign bodies, food impactions, migration of medical devices into the digestive tract (dental prostheses) are common situationse specially among the elderly. Most of these foreign bodies pass naturally through the digestive tract. Complications are rare but can be severe, with esophageal perforation being the most common and feared [1].

The oesophagus is a rather passive organ and its peristalsis is not strong enough to prevent its retaining swallowed denture. For this reason, the most common site of impaction of ingested denture is esophagus [2].

Three modalities of the management of denture ingestion are various, amongst them advanced into the stomach objects not easily grasped in the esophagus like denture, where retrieval may be facilitated. This approach, however, provides no airway protection, and does not directly visualize the esophagus for underlying pathology or complications such as mucosal injury, and lacks control over the object as it is advanced into the stomach. Therefore, endoscopic approaches are recommended [3, 4].

The main contraindication for endoscopic removal of ingested denture is a high risk in cases of complications, such as perforation or abscess or failure of endoscopic removal open surgery via transcervical approach is traitement of choice; transcervical esophagotomy [5].

## Case Report

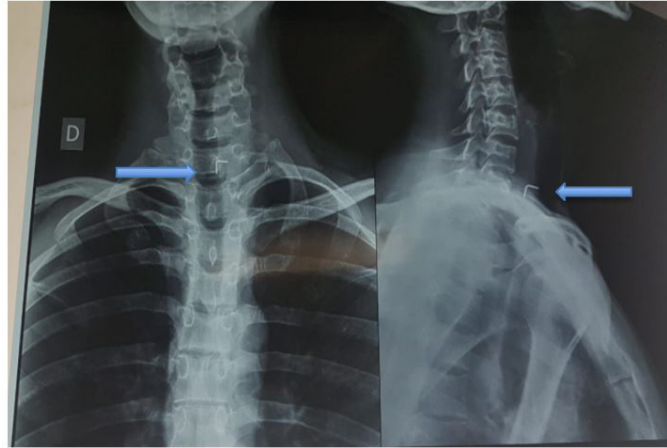
A 32-year-old man presented on October 30, 2018, with a diagnosis of foreign body impacted in the esophagus occurring 5 day previously. He had dysphagia, and regurgitation of food with hypersialorrhea and and foreign-body sensation in the pharynx. She

had an associated history of epilepsy. he had accidentally swallowed her four-tooth removable denture (metal wire fixed denture) during accidental fall at home following an epileptic crisis. Systemic physical examination was within normal limits.

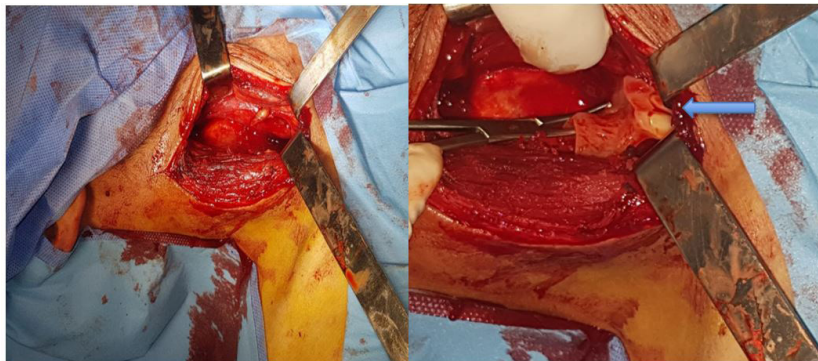
Findings Cervico-Thoracic X-rays demonstrated the clasp of the partial denture at the height of the seventh cervical vertebrae (Figure 1). A rigid esophagoscopy revealed an impacted denture in the esophagus.

The removal endoscopically by rigid esophagoscopy has no successfully, therefore a transcervical esophagotomy has been realized without any incident (Figure 2). The nasogastric tube has been established and the patient was administered antibiotic.

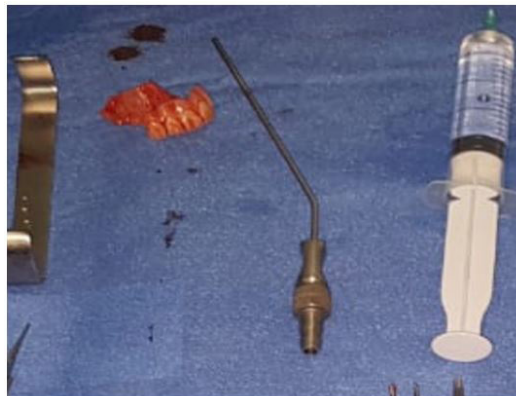The denture was cleaned and returned to the patient (Figure 3) Postoperatively, oral feeds resumed on the fifteenth postoperative day after removal of the nasogastric tube. The patient recovered uneventfully and discharged on 72<sup>th</sup> postoperative day.



**Figure 1:** Cervico-Thoracic X-ray show the clasps of the impacted denture (arrows)



**Figure 2:** The picture showing the removed denture (arrows) by transcervical esophagotomy



**Figure 3:** The picture showing the removed denture with a wire on one side

## Discussion

Voluntary and involuntary Food bolus impaction and Foreign body ingestion are frequently seen in people of all ages, in most cases (80–90%) they pass through the digestive tract, but sometimes they stop and impacts the upper aerodigestive tract require endoscopic extraction and only 1% of cases need Cervical Esophagotomy [6,7].

The presence of anatomical and pathological (benign “inflammatory stricture”, and post-surgical or malignant stenosis and dyskinesias) narrowing of the lumen explain the arrest of a foreign body in this location [8]. Also, the foreign body may have metal clasps predispose them to impaction when ingested; meat bones and Dentures are most commonly found impacted esophageal foreign bodies in adults [9].

Common clinical signs are dysphagia, hypersialorrhea, vomiting, chest strain, , and dyspnea if there is tracheal compression. Complications occur during, after removal or in the late stage when the erosion, or infection cause mucosal ischemia and necrosis [10] radiological examination is the next step to complete the diagnosis, evaluate, size, number, plan removal approach and recognition of complications, possibly showing mediastinal, air or pleural effusion; Neck, chest, and abdominal imaging studies (simple X-ray or CT) should be performed in anteroposterior and lateral views [6,11].

the proximity of vital organs around the esophagus makes many serious complications, including perforation, fistula, retropharyngeal abscess, mediastinitis, hydrothorax, pneumothorax, , pneumomediastinum The risk of complication is 25% higher in the upper esophagus [6].

Rigid and flexible esophagoscopes have been used for Management of impacted foreign body from the esophagus, the rigid esophagoscopes remains the preferred option of management, with success rate of ranges between 94 and 100%, but the need for open surgery to remove the foreign body as a rescue procedure to endoscopy or the primary procedure has not been well defined [10,12].

Surgery is not a defeat for the endoscopist, but alternatively is the best treatment for the patient when retrieval was not removal by other methods or when the patient developed complications, , we found some favorable conditions for a surgical approach During the analysis of the literature , in most cases, endoscopic failure and in cases of complications, such as ; the presence of abscess and/or perforation were the main causes, moreover elongated time since ingestion, and the type and size of the foreign body, growing the probability of need for surgical treatment [6,13].

## Conclusions

The esophagus is a fibromuscular tube that begins around the sixth cervical vertebra and has of points where obstruction or impaction most commonly occur prior reaching the stomach.

Dentures can be accidentally ingested. Denture loosening leads to accidental denture ingestion during an epileptic crisis. Patients with denture loosening should be recommended to visit dentist as soon as possible.

Overall, the success of the treatment of denture ingestion is early diagnosis, prompt and proper decision-making and treatment started without delay.

## References

1. Steven OI, Terry LJ, Michelle AA, Vasundhara A (2011) Management of ingested foreign bodies and food impactions *Gastrointestinal Endoscopy* 73: 1085-91.
2. Nandi P, Ong GB (1978) Foreign body in the esophagus: review of 2394 cases. *Br J Surg* 65: 5-9.
3. Faigel DO, Fennerty MB (1999) Miscellaneous diseases of the esophagus. In Yamada T. (eds): *Textbook of gastroenterology*. Philadelphia (Pa): Lippincott Williams & Wilkins 1304-25.
4. Webb WA (1995) Management of foreign bodies of the upper gastrointestinal tract: update. *Gastrointest Endosc* 41: 39-51
5. Shreshtha D, Sikka K, Singh CA (2013) Foreign body esophagus: when endoscopic removal fails. *Indian J. Otolaryngol. Head Neck Surg* 65: 380-82.
6. Pasquale Cianci (2018) Cervical Esophagotomy for Foreign Body Extraction: A Case Report and Extensive Literature Review of the Last 20 Years. *Am J Case Rep* 19: 400-5
7. Bronstein AC, Spyker DA, Cantilena LR (2007) Annual Report of the American Association of Poison Control Centers' National Poison Data System (NPDS): 25th Annual Report. *Clin Toxicol (Phila)* 46: 927-1057.
8. Kirchner GI, Zuber-Jerger I, Endlicher E (2011) Causes of bolus impaction in the esophagus. *Surg Endosc* 25: 3170-74.
9. Webb WA (1995) Management of foreign bodies of the upper gastrointestinal tract: update. *Gastrointest Endosc* 41: 39-51.
10. Diva Shreshtha, Kapil Sikka, Chirom Amit Singh, Alok Thakar (1988) Foreign Body Esophagus: When Endoscopic Removal Fails... *Indian J Otolaryngol Head Neck Surg*.
11. Pinto A, Muzj C, Gagliardi N (2012) Role of imaging in the assessment of impacted foreign bodies in the hypopharynx and cervical esophagus. *Semin Ultrasound CT MR* 33: 463-70.
12. Brady PG (1990) Endoscopic removal of foreign bodies. In: Silvis SE (ed) *Therapeutic gastrointestinal endoscopy*. IgakuShoin, New York.
13. Herranz-Gonzalez J, Martinez-Vidal J, Garcia-Sarandeses A, Vazquez-Barro C (1991) Esophageal foreign bodies in adults. *Otolaryngol Head Neck Surg* 105: 649-54.