

## CASE REPORT

## Intraorbital Abscess Concomitant with Subperiosteal Abscess in a Two Year-Old Boy. A Rare Case Report

Elias R<sup>1</sup>, Alain A<sup>2</sup>, Elie A<sup>3</sup>, Jihane M<sup>4</sup>, Bassem Abou M<sup>4\*</sup>, and Ghassan Abi Ch<sup>5</sup>

<sup>1</sup>Faculty of Medical Sciences, Department of Otolaryngology, Lebanese University, Beirut, Lebanon

<sup>2</sup>Faculty of Medical Sciences, Department of Radiology, Lebanese University, Beirut, Lebanon

<sup>3</sup>Otolaryngology Specialist, Department of Otolaryngology, Sacre-Coeur Hospital, Hazmieh, Lebanon

<sup>4</sup>Faculty of Medical Sciences, Department of Pediatrics, Lebanese University, Beirut, Lebanon

<sup>5</sup>Interventional Radiology, Department of Radiology, Sacre-Coeur Hospital, Beirut, Lebanon

**\*Corresponding author:** Bassem Abou M, Associate Professor of Clinical Pediatrics, Faculty of Medical Sciences, Department of Pediatrics, Lebanese University, Beirut, Lebanon, Tel: 0096170722205, E-mail: bassemaboumerhi@gmail.com

**Citation:** Elias R, Alain A, Elie A, Jihane M, Bassem Abou M, et al. (2018) Intraorbital Abscess Concomitant with Subperiosteal Abscess in a Two Year-Old Boy. A Rare Case Report. J Otolaryngol Res 1: 102

**Article history:** Received: 21 April 2018, Accepted: 29 May 2018, Published: 31 May 2018

### Abstract

Sinusitis is common among children and it can lead to orbital complications. Here, we present a case of 2 year-old boy that, following ethmoidal sinusitis, developed symptoms and radiological features compatible with subperiosteal abscess. It was treated surgically but the patient presented again with the same initial complaints. He turned out to have an intraorbital extension localized in the extra conal space discovered during a second endoscopic decompression. We presented a case of orbital complication secondary to ethmoidal sinusitis. The patient had a sub periosteal abscess associated with an intraorbital component which the imaging and clinical findings could not identify due to the unusual presentation.

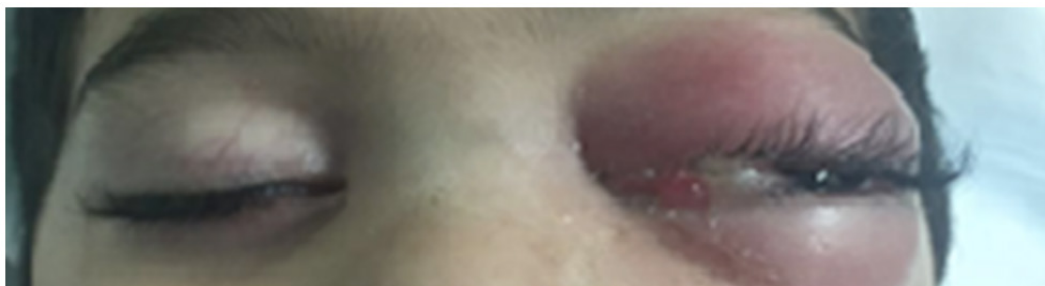
**Keywords:** Subperiosteal; Intraorbital

### Introduction

Sinusitis is a common disease among children. It can lead to serious complications such as orbital infections in 5-7% of cases [1]. The majority of cases in childhood respond to medical treatment. However, if not appropriately treated, they can lead to devastating complications including blindness [2]. In this work, we will present the case report of a patient who developed an orbital complication following ethmoid and maxillary sinusitis. He was diagnosed and treated for sub periosteal abscess; however he turned out to have an abscess with double components: sub periosteal and intraorbital.

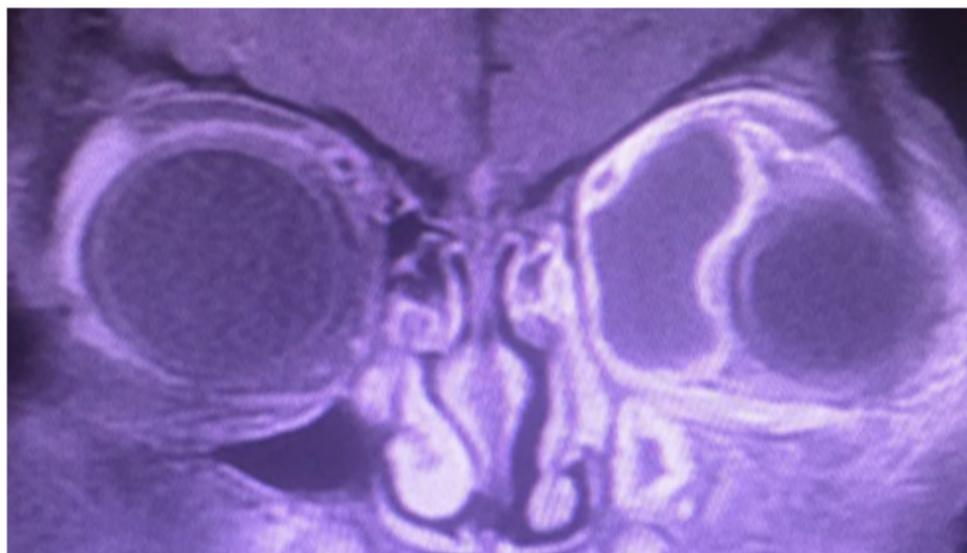
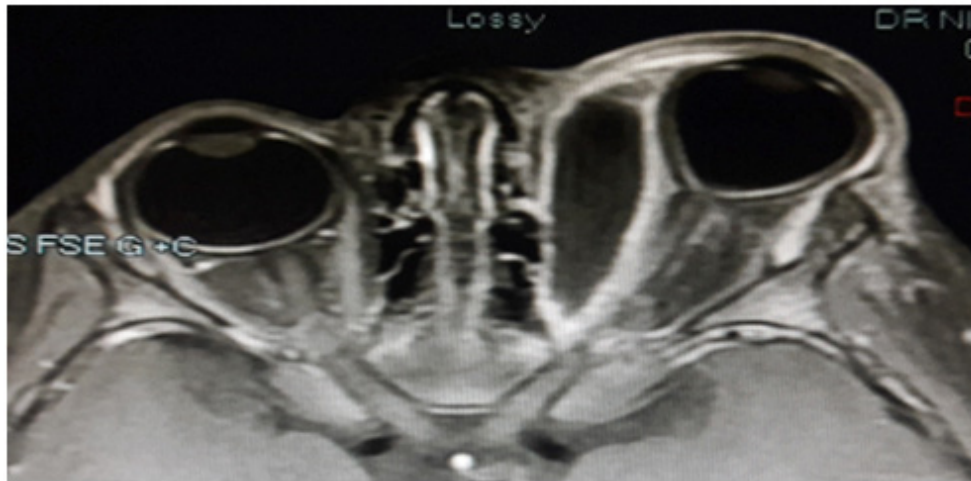### Case Report

A 2 year-old boy was referred to the ER in May 2016 for sudden onset of left orbital swelling and erythema, proptosis and exophthalmus but with no signs of ophthalmoplegia (Figure 1).



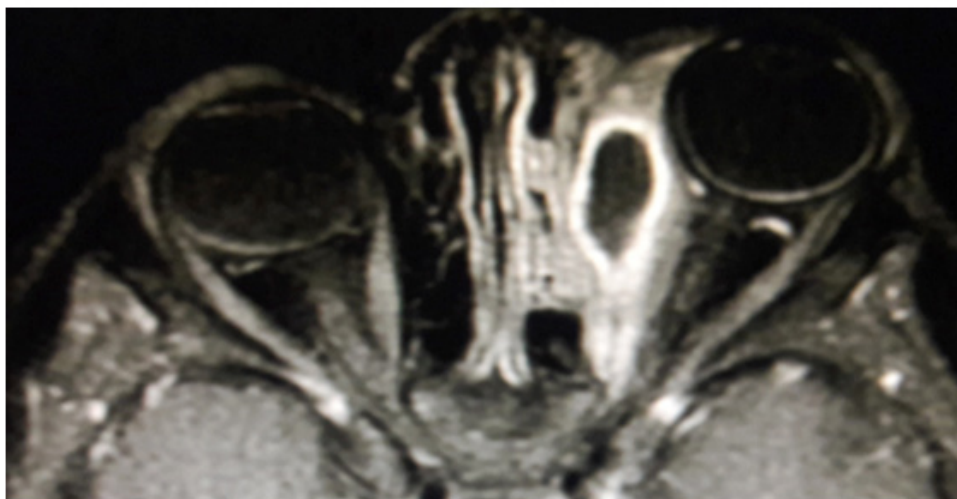
**Figure 1:** Patient on presentation with marked left peri-orbital swelling and erythema, proptosis, exophthalmus and severe chemosis

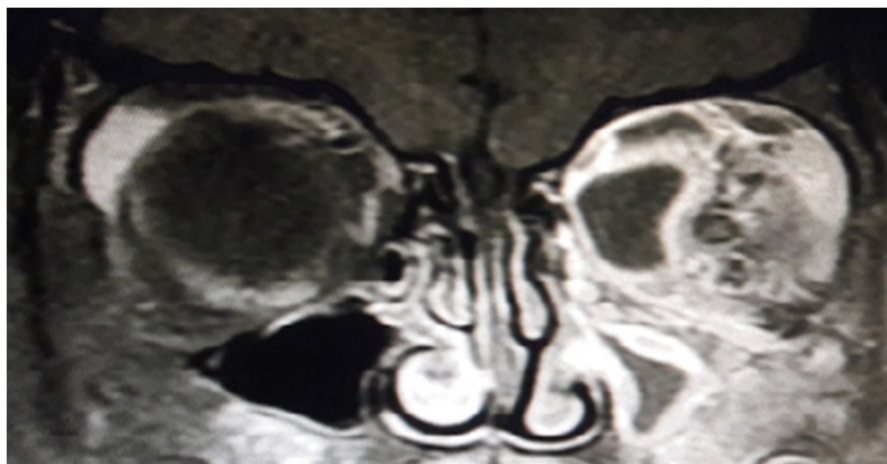
CT-scan showed left maxillary and ethmoid sinusitis associated with a sub periosteal abscess located medial to the medial rectus muscle. Despite intravenous antibiotics, the patient did not improve, so MRI of the orbits was performed revealing persistence of the sub periosteal abscess without involvement of the orbital muscles or the optic nerve (Figure 2).



**Figure 2:** Axial and coronal T1 Fat SAT with Gadolinium MRI sequence showing subperiosteal abscess

Orbital decompression was performed urgently through an endoscopic approach with opening of the lamina papyracea and pus drainage. The patient improved and was discharged on antibiotics, however, he returned to the hospital four days later for the same initial complaint. MRI of the orbits was repeated showing again the presence of a sub periosteal abscess but smaller in size than the initial one (Figure 3).





**Figure 3:** Axial and coronal T1 Fat SAT + Gadolinium MRI sequence showing persistence of the subperiosteal abscess after the first surgery

Urgent decompression was again performed. No collection was found between the remaining part of the bony medial orbital wall and the periorbita, so the latter was incised and an abscess was identified and drained from the intra-orbital space. The boy markedly improved and his eye is almost normal on physical exam 10 days after the second surgery.

## Discussion

The ethmoid sinus is the most commonly implicated sinus in orbital complications in children. In fact, the medial wall of the orbit is made by the lateral ethmoid bone, also called the lamina papyracea. It is very thin and porous thus facilitating the direct spread of infections [3]. Chandler has classified orbital infections into 5 groups according to the location and type of inflammatory process [4]. Among these groups, the subperiosteal abscess results from collection of purulent material between the orbital bony wall and the periosteum, in contrast to the orbital abscess in which the collection is localized in the orbital soft tissue within the periorbita, a fibro-elastic membrane covering the orbital structures [5]. As long as the infection is confined to the subperiosteal plane, there is no impairment of vision or ophthalmoplegia which, on the other hand, occur in almost all patients with intraorbital infections [4]. Concerning the imaging modalities used in orbital infections, CT-scan is considered the gold standard for diagnosis of orbital infections. It is indicated when there is high clinical suspicion of post-septal infections and intra-cranial complications, inability to fully evaluate the eye because of gross edema, or in case of non-response to treatment within 24-36 hours [6]. MRI is helpful for evaluating intracranial extension of infection including cavernous sinus thrombosis, involvement of the optic nerve as well as better assessment for eventual surgical procedures [7]. Intraorbital infections usually result in infiltration of the retro-orbital fat and orbital muscles with involvement of the optic nerve. In our case, both the imaging and the clinical findings oriented the diagnosis towards subperiosteal abscess since there were no signs of ophthalmoplegia and no involvement of the optic nerve or the retro-orbital fat on MRI. In fact, the patient turned out to have an abscess with double components: subperiosteal and intraorbital, which is an unusual presentation.

## Conclusion

Intraorbital infections are serious complications of bacterial sinusitis that should be diagnosed and treated early to prevent serious complications. In the reported case, imaging was not able to differentiate between subperiosteal and intraorbital extraconal abscess. Since the absence of signs of ophthalmoplegia does not exclude intra-orbital extension, it is essential to carefully follow the clinical and radiological evolution after beginning of the treatment in order to exclude intraorbital extension.

## Acknowledgement

We are immensely grateful to Scholarena, open access publishers for their support in dissemination of our work. Authors acknowledge the immense help received from the Scholarena whose articles are cited.

## References

1. Brook I (2013) Acute sinusitis in children. *Pediatr Clin North Am* 60: 409-24.
2. Chaudhry I A, Shamsi FA, Elzaridi E, Al-Rashed W, Al-Amri A, et al. (2007) Outcome of treated orbital cellulitis in a tertiary eye care center in the middle east. *Ophthalmology* 114: 345-54.
3. Givner LB (2002) Periorbital versus orbital cellulitis. *Pediatr Infect Dis J* 21: 1157-8.
4. Lam Choi VB, Yuen HK, Biswas J, Yanoff M (2011) Update in Pathological Diagnosis of Orbital Infections and Inflammations. *Middle East Afr J Ophthalmol* 18: 268-76.
5. Hatano A, Shiwa M, Iimura J, Tsukidate T, Moriyama H (2006) Surgical management of subperiosteal abscess of the orbit. *Nihon Jibiinkoka Gakkai Kaiho* 109: 447-54.

6. LeBedis AS, Sakai O (2008) Nontraumatic Orbital Conditions: Diagnosis with CT and MR Imaging in the Emergent Setting. *RSNA Vascular and Other Emergencies in the Head* 28.
7. Herrmann BW, Forsen JW (2004) Simultaneous intracranial and orbital complications of acute rhinosinusitis in children. *Int J Pediatr Otorhinolaryngol* 68: 619-25.