Open Access

SCHOLARENA

Journal of Neuroscience and Neuropsychology

CLINICAL IMAGE

ISSN: 2577-7890

Hyperostosis Cranii with Various Clinical Symptoms

Takeshi I[1*], Hirohisa O[1] and Yoshihisa Y[2]

[1]*Department of Neurology, Kawasaki Municipal Tama Hospital, Japan*

[2]*Department of Neurology, School of Medicine St. Marianna University, Japan*

[*]**Corresponding author:** Takeshi I, Department of Neurology, Kawasaki Municipal Tama Hospital, Japan, Tel: +81449338111, E-mail: t2imai@marianna-u.ac.jp

Citation: Takeshi I, Hirohisa O, Yoshihisa Y (2021) Hyperostosis Cranii with Various Clinical Symptoms. J Neurosci Neuropsyc 4: 101

Introduction

A 74-year -old woman who was rushed to our hospital for sezure. She had a two-year history of primary stabbing headache and memory disturbance from six months before. Electroencephlography showed transient generalized spike and slow wave complexed over the temporal lobe. We diagnosed temporal lobe epilepsy (TLE) based on the above findings. After the antiepileptic drug and non-steroidal anti-imflammatory drug treatment was started, epileptic seizure and headache gradually improved. T1-weighted and T2-weighted magnetic resonance imaging indicated cerebral parenchyma compressed by the thickness of the bones, and no dilatation of the inferior horn of the lateral ventricle (Picture A and B, arrows). We diagnosed elderly case of hyperostosis cranii with TLE, dementia, and headache.Significant bilateral skull thickening may promote temporal lobe atrophy of the brain parenchyma, leading to cognitive decline and epileptic seizure. This case was improved by antiepileptic drugs, but usually TLE is the most common drug-resistant epilepsy in adults. If head MRI findings such as this case are observed, it is necessary to explain the possible risks to the patient so that they can be dealt with promptly.

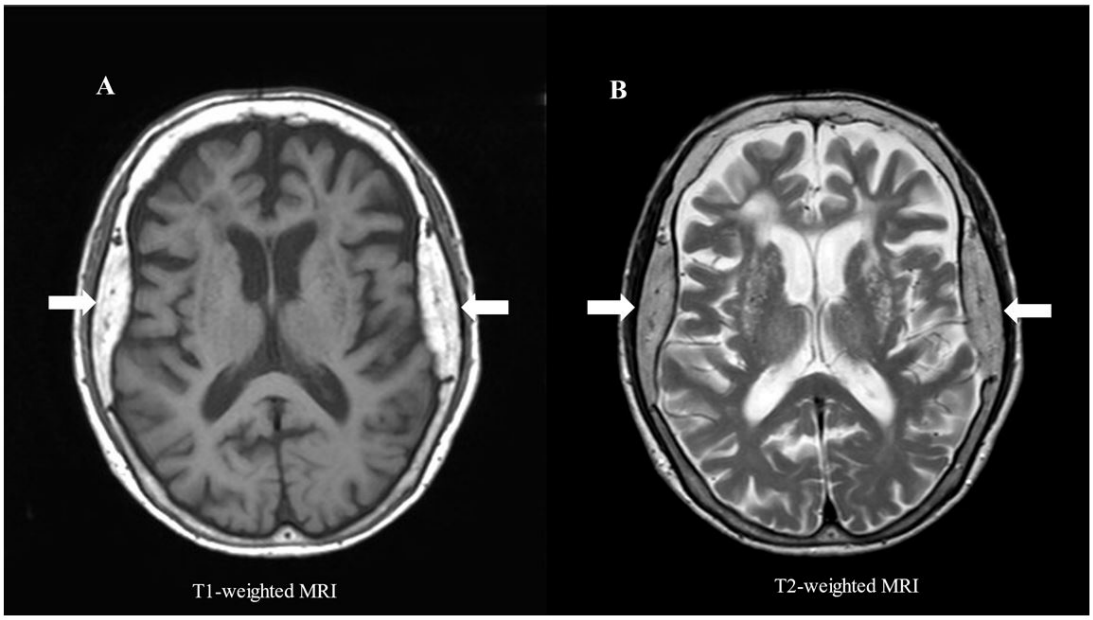

Significant Thickening of the Skulls on both sides compresses and atrophies the temporal lobes on both sides.

Figure 1: Magnetic resonance Imaging (MRI) T1-weighted (A), MRI T2-weighted (B)

Therefore, we suggest that head MRI should be performed to check for deformation of brains by skull of elderly patients whose presenting symptoms include epilepsy, dementia, headache, psychiatic disease.

The authors state that they have no Conflict of Interest (COI).

References

1. Lorenzo Caciagli, Andrea Bernasconi, Samuel Wiebe, Matthias J Koepp, Neda Bernasconi, et al. (2017) A meta-analysis on progressive atrophy in intractable temporal lobe epilepsy: Time is brain? Neurol 89: 506-16.

2. Marina KM Alvim, Ana C Coan, Brunno M Campos, Clarissa L Yasuda, Mariana C Oliveira, et al. (2016) Progression of gray matter atrophy in seizure-free patients with temporal lobe epilepsy, Epilepsia 57: 621-9.

3. E Bilevicius, CL Yasuda, MS Silva, CAM Guerreiro, I Lopes-Cendes, et al. (2010) Antiepileptic drug response in temporal lobe epilepsy: a clinical and MRI morphometry study. Neurol 75: 1695-1701.

4. Simon S Keller, Mark P Richardson, Jan-Christoph Schoene-Bake, Jonathan O'Muircheartaigh, Samia Elkommos, et al. (2015) Thalamotemporal alteration and postperative seizures in temporal lobe epilepsy. Ann Neurol 77: 760-74.