

Diagnosis of Retinal Detachment by Ultrasound in the Emergency Department: Case Report

Cardozo A*

Emergency Medicine Physician Special Care Unit, CES Clinic Medellin, Colombia

***Corresponding author:** Cardozo A, Emergency Medicine Physician Special Care Unit, CES Clinic Medellin, Colombia, Tel: +057 3164728917; E-mail: galeno026@gmail.com

Citation: Cardozo A (2020) Diagnosis of Retinal Detachment by Ultrasound in the Emergency Department: Case Report. J Emerg Med Care 3: 103

Article history: Received: 10 February 2020, Accepted: 05 June 2020, Published: 09 June 2020

Abstract

Bedside Ultrasound contributes to the diagnosis of rare conditions in the emergency department. For the case of ocular Ultrasound, pathologies such as traumatic hemorrhage, ocular rupture, vitreous hemorrhage, lens dislocation and even foreign bodies have been reported. Below we present the diagnosis given by emergency physicians about retinal detachment using Ultrasound.

Keywords: Point of Care Ultrasound; Retinal Detachment; Eye Emergencies

Introduction

Retinal detachment is a rare pathology served at the Emergency department, it stands for 6.3 to 17.9 per 100.000 inhabitants [1], and as it is an emergency case, it is necessary to make a timely diagnosis in order to achieve a better visual result between 1 and 7 days [2,3] Below we are presenting the case of a patient whose retinal detachment diagnosis was performed through the point-of-care Ultrasound at the emergency department.

Case

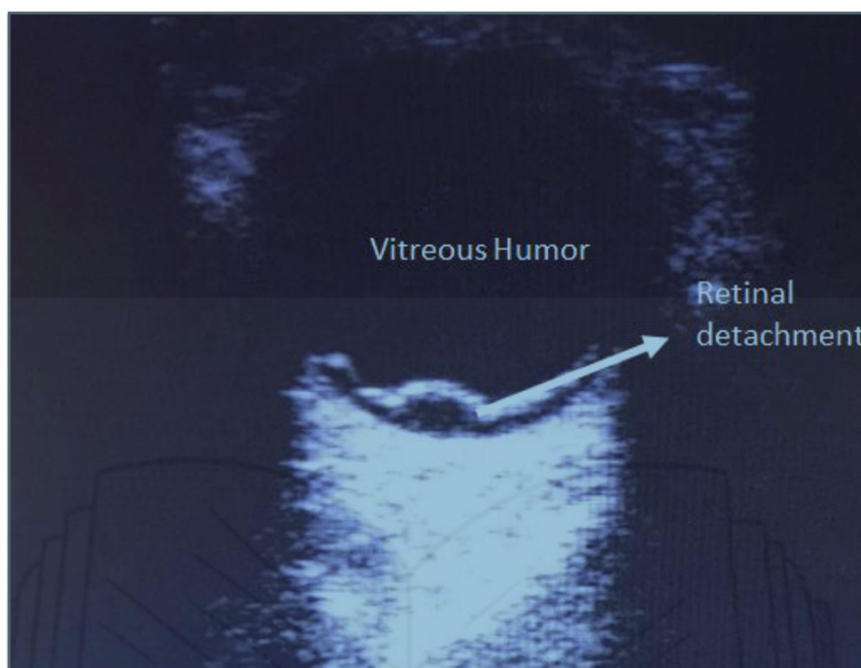

Figure 1: Retinal detachment

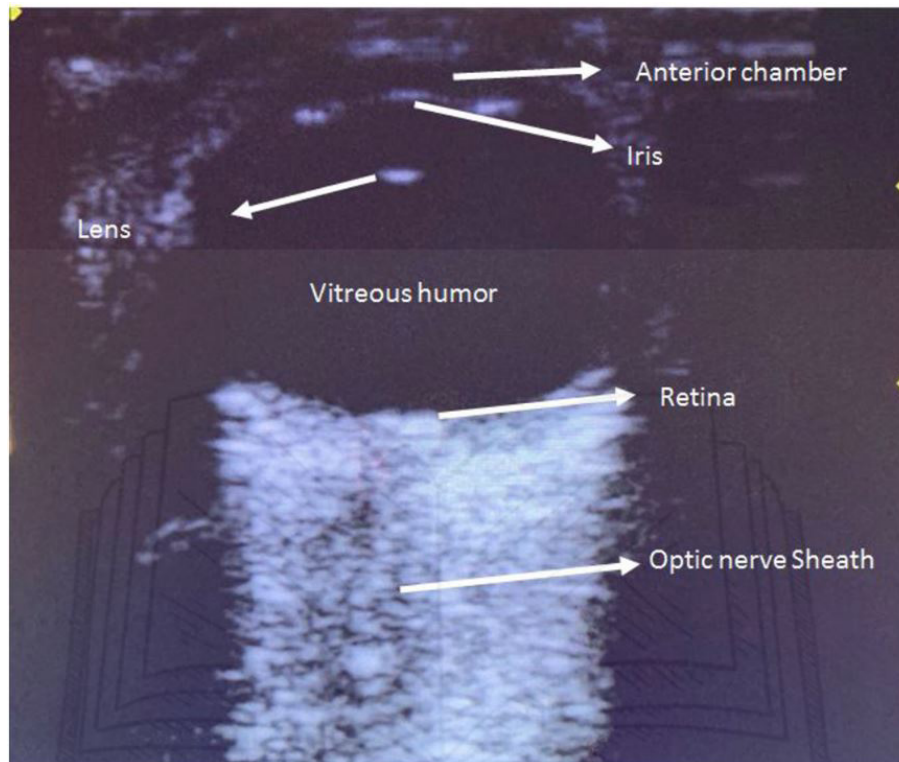


Figure 2: Normal eye anatomy

A 37-year old female patient came to our emergency department for a consultation with mild obesity (Body Mass Index [BMI]: 32) with a migraine history with visual aura, whose typical headache started five days ago accompanied by photopsies, sonophobia, and nausea. She was prescribed with sumatriptan and acetaminophen providing her a pain partial improvement. Forty eight hours before consultation her pain decreases to a 2/10 intensity, but she finds out that although her visual symptoms worked out, her left eye loses the visual field when seeing towards left, describing “a curtain being partially closed”. By the time she is admitted in the urgencies department her blood pressure is 142/70, her pulse 73; her neurological exam without facial asymmetries, no pupillary abnormalities, no nystagmus or abnormalities in eye movements and, pupils were isochoric but miotic which turned out ophthalmoscopy to be inconclusive. Because of the above, and considering the possibility of an eye pathology, it is decided to perform a bedside ocular Ultrasound using palmsize well2 3100 (Chenzen-China) 6 – 9 mghz ultrasonograph linear transducer over the left eyelid, previous abundant gel. It can be seen in the cross axis in the posterior segment (Figure 1) an image in the form of an hyperechoic wavy membrane, which is compatible with the retinal detachment, non-existing image when compared with the contralateral eye (Figure 2). Because of the foregoing, she is referred to ophthalmology where the suspected diagnosis is confirmed and a successful treatment done.

Discussion

Retinal detachment is a rare entity at the emergency department [1,2]. They are patients that make consultation due to acute loss of vision, decreased visual acuity, or the description of darkness in the visual area [3]. The following are the risk factors for this pathology: myopia, trauma history, over 65 years old, BMI > 30, family history on retinal detachment, previous eye surgery, Marfan Syndrome [4].

There are mechanical mechanisms that keep the union between the pigmented retinal epithelium and sensorineural retina, detachment is characterized by the presence of a retinal thick break which is held due to the vitroretinal traction allowing the liquid accumulation in that space. Some metabolic factors such as the decrease of oxygenation at the vitroretinal union also decrease the retinal adhesion resulting in either a perpetuation of the defect or a predisposition to it [5]. For determining the diagnosis; the visual acuity, the visual fields by confrontation and the fundus of the eye are necessary for its initial approach, in the latter, an injury of wavy and mobile appearance is being searched, which stretches from the ora serrata to the optic nerve, and syneresis of the vitreous and traction can also be seen [6]. When the physical examination is inconclusive, magnetic resonance imaging and computer tomography are useful [7,8].

Descriptions of the tomographic and resonance findings in retinal detachment have been described [9]; Comparisons between resonance and ultrasound have been performed in posterior segment pathologies, although not directly in retinal detachment suggesting ultrasound can be superior [10]. Ultrasound to the patient's bedside has acquired an important role in recent years regarding the assessment of eye pathologies due to its availability and ease to make it with a 30-minute training, and it is another safe option detecting the retinal detachment up to – 94%, with a specificity up to 96% [11,12].

High-frequency (linear) transducers are required for its accomplishment which are to be located in the upper lid area with the eye closed, avoiding the contact of the transducer with the skin by covering it with transparent dressings or abundant gel to create a film between the skin and the transducer, since the eye is a spherical structure, the scan can be performed on the longitudinal and transverse axis, lens behaves as a structure, anatomically separating the anterior from the posterior segment, so once it is identified, the anatomic localization of visualized injuries can be known. Lens dislocation, eyeball rupture, retinal and vitreous hemorrhage, and foreign bodies have been reported [13]. Ocular ultrasonography allows the evaluation of patients with ocular trauma, non-traumatic vision changes, and presence of intracranial hypertension through the measurement of the optic nerve sheath, search of retroocular injuries, optic neuritis, abscesses, foreign bodies or tumors. Some protocols such FOVEA can be useful for the systematic approach of eye injuries [14,15].

Regarding the retinal detachment, it is visualized as a hyperechoic and wavy line originated from the posterior wall increasing its undulation with the eye movements [16]. In conclusion, ultrasonography at the patient's bedside is a safe tool allowing the treatment of some rare ophthalmological conditions in the emergency department allowing the physical examination to be complemented and facilitating the disposition without compromising the patient safety.

References

1. Mistry D, Charteris DG, Fleck BW, Campbell H, Singh J (2010) The epidemiology of rhegmatogenous retinal detachment: Geographical variation and clinical associations. *Br J Ophthalmol* 94: 678-684.
2. Orban M, Islam YFK, Haddock LJ (2016) Timing and Outcomes of Vitreoretinal Surgery after Traumatic Retinal Detachment. *J Ophthalmol*.
3. Walker CB (2014) Retinal Detachment. *Am J Ophthalmol* 17: 1-17.
4. Mattioli S, Curti S, De Fazio R, Farioli A, Cooke R, et al. (2009) Risk Factors for Retinal Detachment. *Epidemiology* 20: 462-70.
5. Ghazi NG, Green WR (2002) Pathology and pathogenesis of retinal detachment. *Eye* 16: 411-1.
6. García Arumí J, Martínez Castillo V, Boixadera A, Blasco H, Marticorena J, et al. (2013) Rhegmatogenous retinal detachment treatment guidelines. *Arch Soc Esp Oftalmol* 88: 11-35.
7. Kang HK, Luff AJ (2008) Management of retinal detachment: A guide for non-ophthalmologists. *Bmj* 336: 1235-40.
8. Hallinan JTPD, Pillay P, Koh LHL, Goh KY, Yu WY (2016) Eye globe abnormalities on MR and CT in adults: An anatomical approach. *Korean J Radiol* 17: 664-73.
9. Dubey P, Jindal G, Lee P, Moonis G (2019) Nontraumatic orbital emergencies. *Seminars in Ultrasound CT and MRI* 40: 95-103.
10. Jacobsen BH, Ricks C, Harrie RP (2018) Ocular ultrasound versus MRI in the detection of extrascleral extension in a patient with choroidal melanoma. *BMC Ophthalmol* 18: 320.
11. Gottlieb M, Holladay D, Peksa GD (2019) Point-of-Care Ocular Ultrasound for the Diagnosis of Retinal Detachment: A Systematic Review and Meta-Analysis. *Acad Emerg Med* 26: 931-9.
12. Kim DJ, Francispragasam M, Docherty G, Silver B, Prager R, et al. (2019) Test Characteristics of Point-of-care Ultrasound for the Diagnosis of Retinal Detachment in the Emergency Department. *Acad Emerg Med* 26: 16-22.
13. Kilker BA, Holst JM, Hoffmann B (2014) Bedside ocular ultrasound in the emergency department. *Eur J Emerg Med* 21: 246-53.
14. Surjya PU, Piyush NM, Waleed E, Vasu K AJ (2018) Emerging Role of Bedside Ocular Ultrasound in Emergency Department and Intensive Care Unit. *Dev Anaesth Pain Manag* 1: 1-5.
15. De La Hoz Polo M, Torramilans Lluís A, Pozuelo Segura O, Anguera Bosque A, Esmerado Appiani C, et al. (2016) Ocular ultrasonography focused on the posterior eye segment: what radiologists should know. *Insights Imaging* 7: 351-64.
16. Kahn A, Kahn AL, Corinaldi CA, Benitez FL, Fox PC (2005) Retinal Detachment Diagnosed by Bedside Ultrasound in the Emergency Department. *Calif J Emerg Med Calif Chapter Am Acad Emerg Med* 6: 47-51.