

## CASE REPORT

# Acute Arterial Occlusions in Patients with COVID-19: Results and Outcomes

de Athayde Soares R\*

*Division of Vascular and Endovascular Surgery, Hospital do Servidor Público Estadual de São Paulo, São Paulo, Brazil*

\***Corresponding author:** de Athayde Soares R, Division of Vascular and Endovascular Surgery, Hospital do Servidor Público Estadual de São Paulo, São Paulo, Brazil, Tel: +5511999813733, E-mail: [drrafaelsoaresvasc@gmail.com](mailto:drrafaelsoaresvasc@gmail.com); [rafaelsoon@hotmail.com](mailto:rafaelsoon@hotmail.com)

**Citation:** de Athayde Soares R (2021) Acute Arterial Occlusions in Patients with COVID-19: Results and Outcomes. J Vasc Surg Res 2: 102

## Abstract

In this paper, we aimed to describe a case series report of four patients that were admitted in the emergency room of our vascular and endovascular surgery department with acute arterial occlusion after a diagnosis of Covid-19 infection. The first patient was a male, 50 years, tobacco user, with arterial systemic hypertension and COVID-19 positive that was admitted with an acute arterial occlusion Rutherford IIB in the left lower limb. He was submitted to an arterial thromboembolectomy with Fogarty catheter and had a satisfactory evolution. CASE 2 was a female, 63 years, with arterial systemic hypertension, diabetes, esquizofrenia, that was admitted with acute limb ischemia (ALI) Rutherford III in the upper left limb. Despite attempts do revascularize the upper limb, the patient evolved with a hand amputation. CASE 3 was a Male patient, 49 years, HIV positive, diabetic with previous debridement in both feet due to diabetic foot infection, tobacco user and Rutherford IIB ALI in the right lower limb. The patient was submitted to an arterial thromboembolectomy with Fogarty catheter, however presented with fasciotomy infection and another post-operative complications that led him to die. Finally, CASE 4 was a female patient, 49 years, diabetic, admitted with COVID-19 infection that presented ALI during hospitalization on the right lower limb. She was submitted to proper thromboembolectomy, with a satisfactory evolution and limb salvage. COVID-19 pandemic crisis is a challenging situation that has increased the number of acute arterial thrombosis and embolism urgencies and emergencies surgeries in the vascular world. The four patients related in this paper bring valuable information regarding the impact of COVID-19 on micro and macrovascular system.

**Keywords:** COVID-19; Acute Limb Ischemia; Thromboembolectomy

## Introduction

Acute limb ischemia (ALI) represents one of the most common emergencies in vascular surgery with incidence range of 22 per 100,000 patients per year [1]. The treatment of ALI is still a challenge for vascular surgeons, considering the clinical severity of the patients. However endovascular treatment may be the preferred treatment of Rutherford I and IIA ALI, whereas open surgery may be the best option for ALI due to arterial embolism and for Rutherford IIB acute arterial thrombosis, because of a greater urgency to restore blood flow [2].

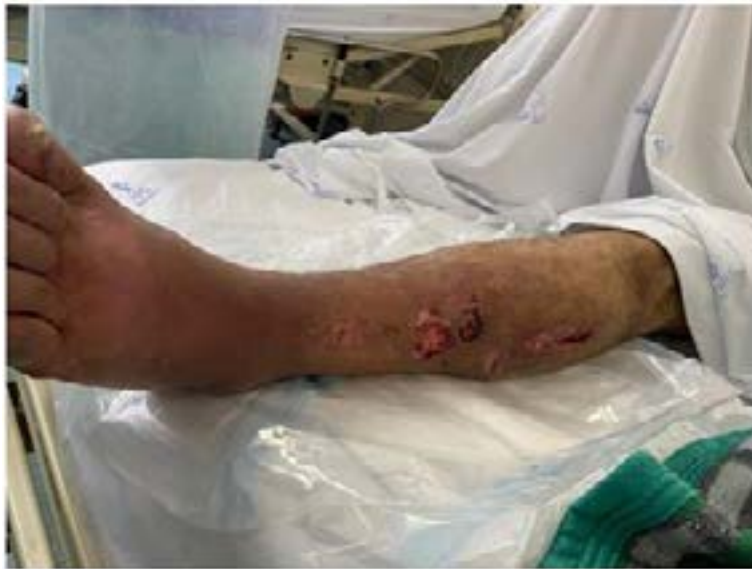The novel coronavirus pneumonia (COVID-19) pandemic has affected the globe and is associated with coagulopathy disorders, therefore the presence of a coexisting hypercoagulable state in patients with COVID-19 might be associated with higher mortality [3,4]. Patients who test positive for COVID-19 could experience a hypercoagulable state that could increase the incidence and extension of native arterial occlusion. A sudden and significant increase of COVID-19–infected patients who were presenting with ALI has been noted at our vascular departments [5].

The objective of this paper is to report a case series of four patients with acute limb ischemia and concomitant COVID-19 infection, their outcomes and a review of the vascular surgery practice during the pandemic infection. This study was approved by the Research Ethics Committee of the South Regional Hospital, São Paulo, Brazil, under the number 34953614.3.000.5463.

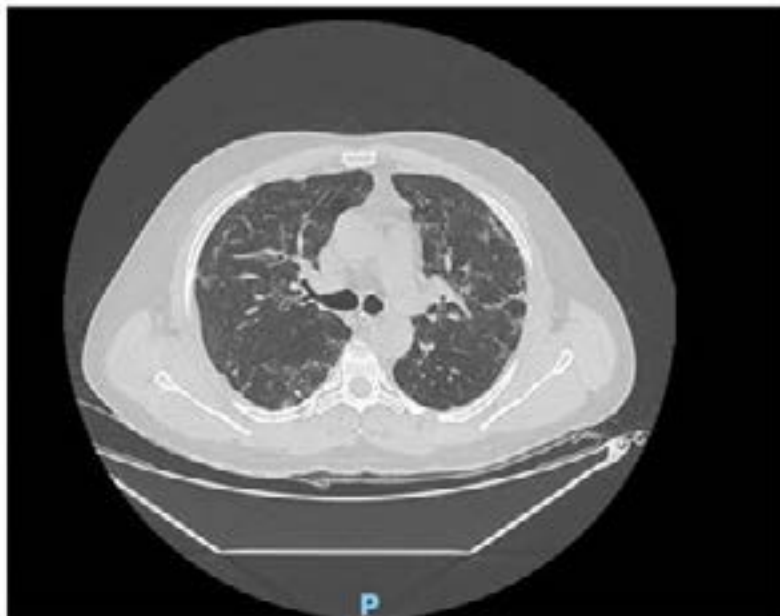
## Case 1

A 50 years male, tobacco user, with arterial systemic hypertension and at the 7<sup>th</sup> day COVID-19 infection was admitted with an acute arterial occlusion Rutherford IIB in the left lower limb. At physical examination he had femoral, popliteal and distal pulses present in

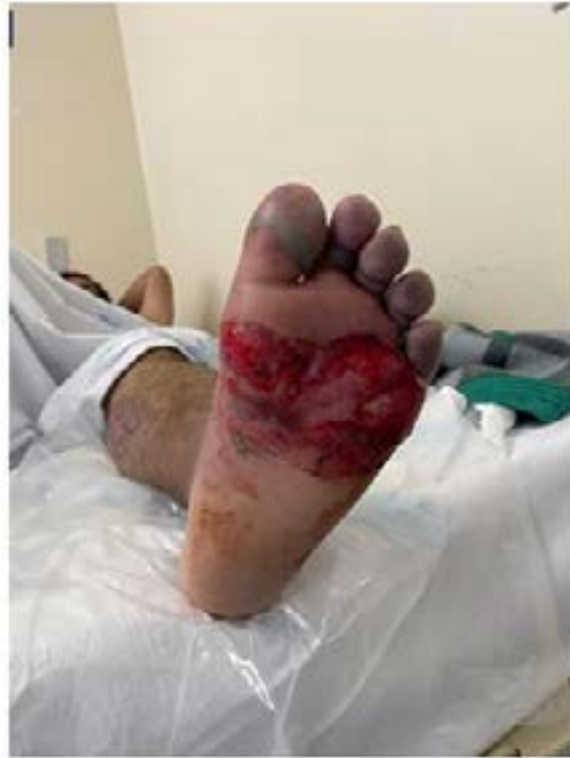the right lower limb, however in the left lower limb he had only femoral pulses, without popliteal and distal pulses. He was submitted to an arterial duplex ultrasound that confirmed femoral superficial artery occlusion, with thrombi in the profunda femoral artery and no detectable flow in the infrapopliteal arteries. At admission the laboratory tests were hemoglobin 11.3g/dl, haematocrit 31.6g/dl, creatinine 0,6 mg/dl, Urea 34mg/dl, D-Dimer 3450 mg/dl and leukocytes  $12 \times 10^8$  cells/l. Under general anesthesia and intravenous non-fractionated-heparin 80 UI/Kg infusion, a standard groin incision was used to expose the femoral bifurcation, with a thromboembolectomy of the profunda and superficial femoral arteries, popliteal artery and infrapopliteal arteries with adequate thrombi removal and blood flow restoration. The patient evolved with popliteal and distal palpable pulses and was submitted to fasciotomies, being forwarded to the intensive care unit, with parenteral enoxaparin 1mg/kg/12/12 hours prescription. At the 4th day post-operative, the patient presented with fasciotomy infection, that was treated with Meropenem (Figure 1). Regarding the pulmonary aspect, the thorax CT-SCAN showed typical COVID-19 findings (Figure 2), without oxygen supplementary necessity. He was discharged in the 18th post-operative day, with borderline cyanosis among the toes (Figure 3), in Warfarin use, in order to wait toe's gangrene delimitation at home. He has been readmitted to the hospital 1 month after the surgery and was submitted to debridement and small toes amputations. (Figure 4). Therefore, he survived COVID-19 infection and his limb was saved.



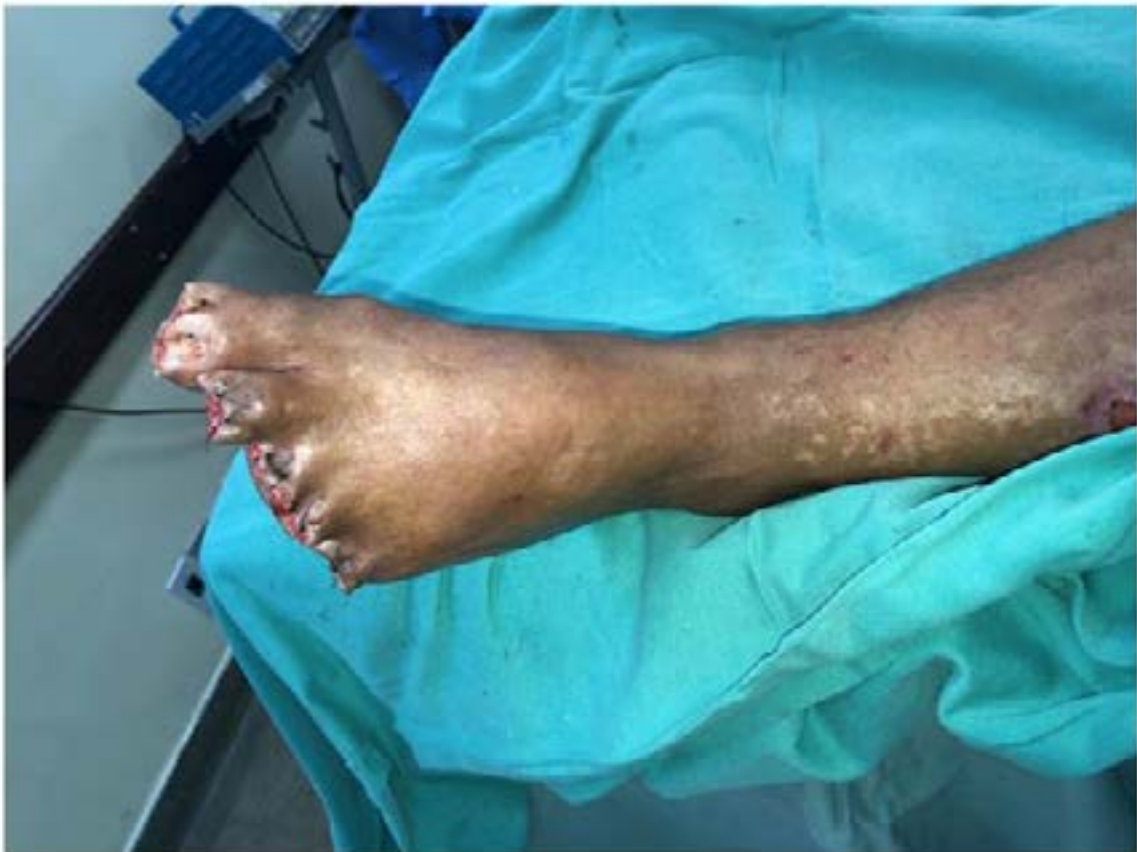**Figure 1:** Fasciotomy infection in CASE



**Figure 2:** Thorax CT-SCAN with COVID-19 findings in CASE 1



**Figure 3:** Borderline cyanosis among the toes and the foot in CASE 1



**Figure 4:** Final aspect of the foot in CASE 1

## Case 2

A female patient, 63 years, with arterial systemic hypertension, diabetes, esquizophrenia and at the 13th day of COVID-19 infection, was admitted with ALI Rutherford III in the upper left limb, with axillary, brachial, radial and ulnar pulses in the right upper limb and no palpable pulses in the left upper limb. At admission the laboratory tests were hemoglobin 13.8g/dl, haematocrit

34.6g/dl, creatinine 1,6 mg/dl, Urea 44mg/dl, D-Dimer 19450 mg/dl and leukocytes  $15.8 \times 10^8$  cells/. Despite the Rutherford III condition and in order to ensure upper limb extremity amputation level, she was submitted to an arterial exploration through direct open brachial artery exposure and thromboembolectomy under general anesthesia and partial restored blood flow, with brachial pulse and without radial and ulnar pulses. At the 1<sup>st</sup> post-operative, the ischemia has progressed and the brachial pulse was absent. The patient was submitted to an angioCT-Scan that showed occlusion at subclavian artery origin. (Figure 5), which led her to a second arterial exploration with brachial access, axillar, brachial, radial and ulnar thromboembolectomy, followed by an origin subclavian ballon-expandable stent implantation 8x39, and axillar artery self-expandable stent 7x60 implantation due to an artery dissection, through right femoral approach. The patient evolved with brachial and radial pulses, without ulnar pulse, and was treated with Clopidogrel and enoxaparin 1mg/kg/12/12 hours. Despite the technical success, the left hand presented with irreversible ischemia (Figure 6), and an increasing at creatinephosphokynase levels (1841 mg/dl), which led to a hand amputation at the 8<sup>th</sup> day post-operative (Figure 7). The patient was discharged at the 4<sup>th</sup> day post-operative hand amputation, with AAS and clopidogrel prescription.

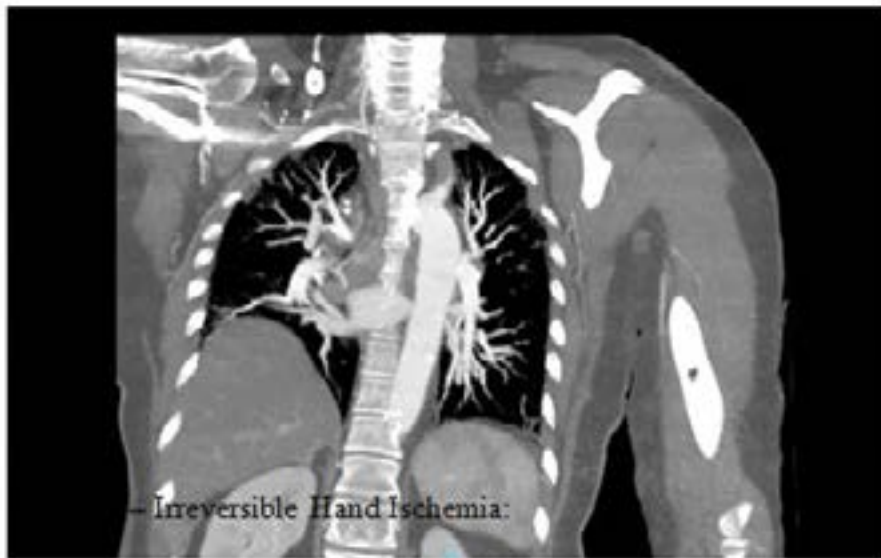

Figure 5: Angio-CT SCAN with subclavian artery occlusion in CASE 2

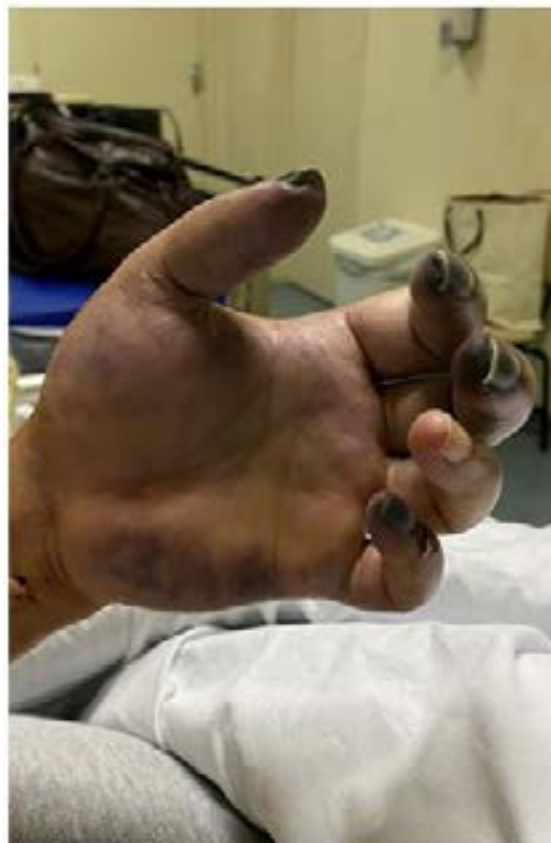
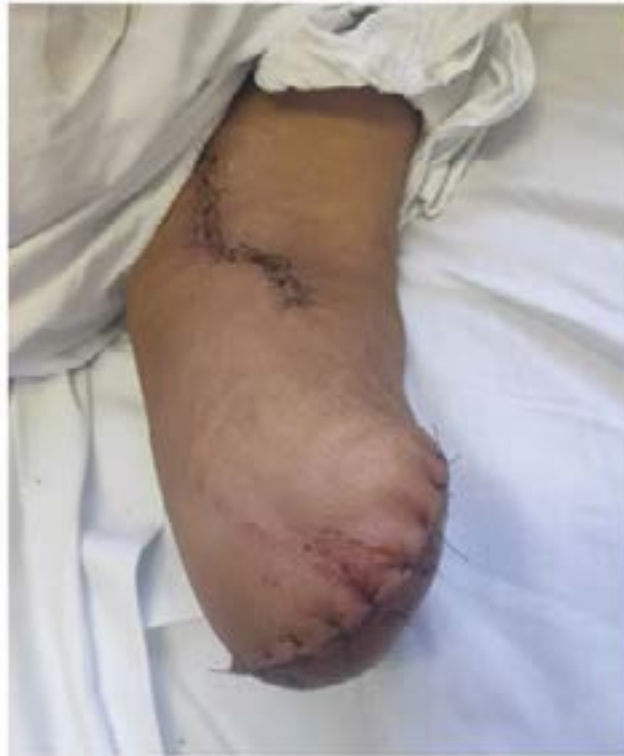
Figure 6: Irreversible Hand Ischemia

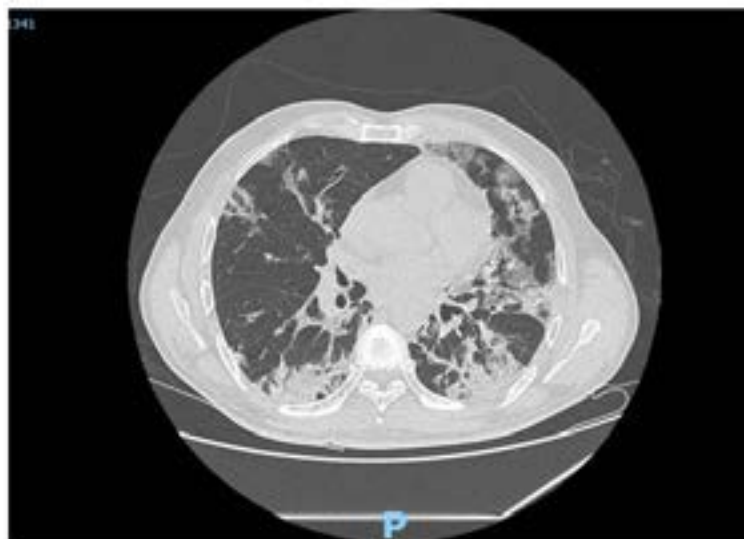




**Figure 7:** Final aspect of the hand amputation

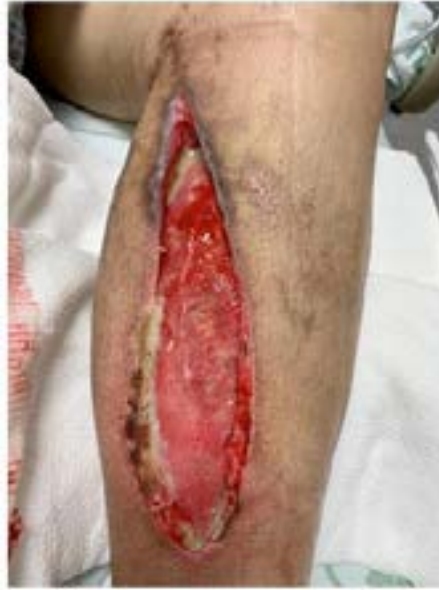### Case 3

A Male patient, 49 years, HIV positive, diabetic with previous debridement in both feet due to diabetic foot infection, and tobacco user was admitted to the emergency room with 5 days history of chest pain, fever and cough. A thorax CT-SCAN (Figure 8) was performed and identified positive signs of COVID-19 infection, which was confirmed with a RT-PCR test. At the 11th day of COVID-19 infection the patient evolved with sudden pain on the right lower limb and absence of palpable pulses all over the limb. The contralateral limb had all palpable pulses. The right limb ALI was confirmed with a duplex SCAN that showed no flow along all arteries and hypoechoic thrombi. At admission the laboratory tests were hemoglobin 16.8g/dl, haematocrit 35.6g/dl, creatinine 1,0 mg/dl, Urea 34mg/dl, D-Dimer 13450 mg/dl and leukocytes  $16.8 \times 10^8$  cells/. Under general anesthesia and intravenous non-fractionated-heparin 80 UI/Kg infusion, a standard groin incision was used to expose the femoral bifurcation, with a thromboembolectomy of the common iliac, external iliac, profunda and superficial femoral arteries and popliteal artery with adequate thrombi removal and blood flow restoration and fasciotomies were performed in the medial and lateral compartment of the leg. The femoral and popliteal pulses were palpable, with an ankle brachial index 0,87. Despite successful blood flow restoration, at the 7th post-operative day the patient started with a fasciotomy infection (Figure 9), which led to Meropenem and Vancomycin prescription. Another surgery was performed in order to realize a debridement and a surgical removal of the infected tissues.



**Figure 8:** Thorax CT-SCAN showing ground glass opacities and the crazy -paving patterns in the lungs

After the surgery, the patient presented with a septic shock, pulmonary and fasciotomy infection, major organic failure, renal impairment and orotracheal intubation, which led to the necessity of trasference to the intesive care unit, hemodynamic instability and death on the 10th post-operative day.

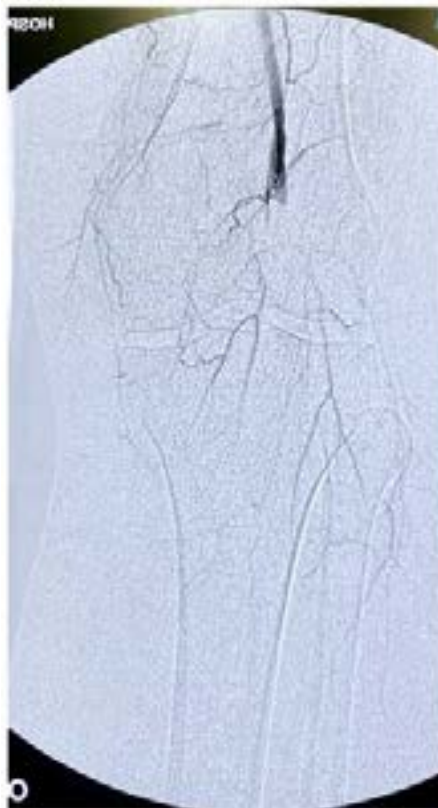

**Figure 9:** infected fasciotomy which led to Meropenem and Vancomycin use

**Figure 11:** Post-opera

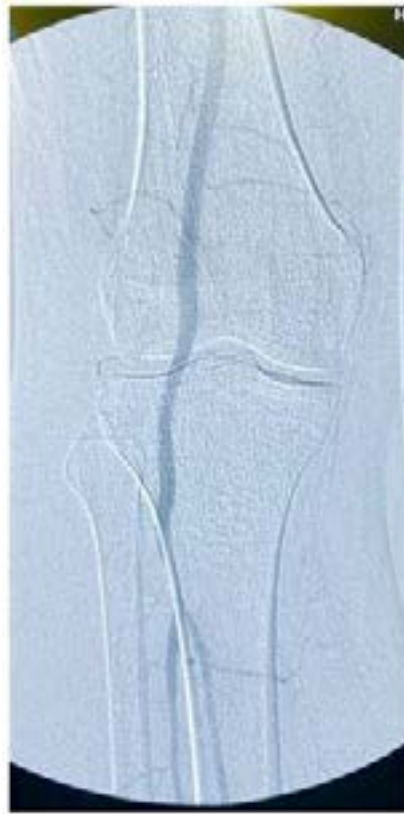#### Case 4

A female patient, 49 years, diabetic, was admitted at the hospital with COVID-19 infection, confirmed with RT-PCR test. The patient was hospitalized and was submitted to clinical treatment with intravenous dexamethasone and enoxaparin 40mg / day. At the 10th day of infection, the patient presented a sudden pain at left lower limb associated with a cyanotic hallux. Initially, the attending physician believed to be a worsening onset of the respiratory tract and initiated clinical treatment with enoxaparin 80mg subcutaneous 12/12 hours. At the 13th day of COVID-19 infection, the patient experienced a worsening of the leg symptoms and a vascular surgery was called to evaluate the patient. At the physical examination the patient had only femoral pulse palpable



**Figure 10:** Preoperative angiography showing popliteal and infrapopliteal arteries occlusion

in the left lower limb with femoral, popliteal and pedal pulses palpable in the right lower limb and a Rutherford IIb acute limb ischemia. D-dimer dosage was 10.859mg/dl and creatinophosphokynase was 5670mg/dl. Under general anesthesia and intravenous non-fractionated-heparin 80 UI/Kg infusion the patient was then submitted to an angiography (figure 10) and a successfully thromboembolectomy of the popliteal and infrapopliteal arteries through infrapopliteal artery dissection and Fogarty 4 and 3 use. A post-operative angiography (Figure 11) showed satisfactory evolution and the patient evolved with popliteal and pedal pulses palpable. The patient was hospital discharged four days after the surgery and had adequate oral anticoagulation with Rivaroxaban 20mg daily with successfully revascularization and limb salvage.



**Figure 11:** Post-operative angiography showing satisfactory blood flow restoration

## Discussion

Abdallah, et al. [6] reported the impact of COVID-19 pandemic on vascular surgery in Paris. The authors observed a rising number of acute arterial events in COVID-19 patients with no prior vascular history. These acute arterial events included acute thrombosis of the abdominal aorta, carotid and peripheral arteries that could be the revealing symptom of COVID-19. They concluded that we will probably face a post pandemic wave of patients with severe vascular conditions. Similarly, in São Paulo, the vascular surgeons are facing an increasing of peripheral acute arterial events among patients infected with COVID-19, sometimes with catastrophic outcomes, such as limb loss and death due to a hypercoagulable state, with microcirculation thrombosis, which leads to limb loss, despite successfully revascularization. The four cases reported at this paper illustrates these catastrophic vascular events, whereas among four revascularizations on limb acute arterial occlusion, one patient had a hand amputation and one patient died during the post-operative.

Inessa, et al. [7] published a paper comparing 16 SARS-CoV-2 positive patients who underwent lower extremity CT angiogram (CTA) of the lower extremities and 32 SARS-CoV-2 negative patients observed from January to April in 2018-2020. All COVID-19 patients (100%, 95%CI: 79-100%) had at least one thrombus while only 69% (95%CI: 50-84%) of controls had thrombi ( $p=0.02$ ). COVID-19 patients presenting with symptoms of leg ischemia only were more likely to avoid amputation or death than patients presenting also with pulmonary or systemic symptoms ( $p=0.001$ ). Among 16 patients with COVID-19 infection, there were 6 deaths (38%) and 4 cases of amputation (25%). These results are very similar with those found in this case serie reports, with 1 death (25%) and 1 hand amputation (25%), among 4 patients with COVID-19 infection.

While the more severe outcomes in COVID-19 patients may reflect greater arterial thrombus burden, which may be a marker of increased mortality by itself, it can also be attributed to the aggressive nature of severe COVID-19 disease, which has been associated with cytokine storm, fulminant myocarditis and atypical hypercoagulability causing development of thromboses despite patients being on therapeutic doses of anticoagulation [8,9]. Moreover, a viral coagulopathy correlating with poor prognosis has been amply described in recent reports in patients with COVID-19 infection who may exhibit pulmonary embolism; venous,

arterial, and microvascular thrombosis; lung endothelial injury; and associated thrombotic complications leading to and/or worsening acute respiratory distress syndrome [10]. D-dimers and fibrin/fibrinogen degradation products are particularly elevated in these patients. However, this coagulopathy is not characterized by consumption of coagulation factors, as seen in disseminated intravascular coagulation.<sup>11</sup> This arterial thrombus burden was specially noted on case 2, where the patient arrived with a severe upper limb arterial occlusion, and despite two attempts to restore blood flow, unfortunately, the patient had a hand amputation. Upper limbs amputations due to arterial ischemia are very rare conditions, where its well known in the literature that the upper limb extremity respond very satisfactory to arterial revascularization.

Another study indicated that high D-dimer levels at initial presentation were predictive of coagulation-associated complications during hospitalization (D-dimer >2500 ng/mL, adjusted odds ratio - OR for thrombosis 6.79, for bleeding 3.56), critical illness, and death.<sup>12</sup> All four patients described in this present paper had high D-dimer levels at initial acute arterial ischemia presentation and all of them received enoxaparin subcutaneous at a chemoprophylaxis dose prior to develop the acute arterial event. According to a multicenter retrospective study of 400 hospital-admitted COVID-19 patients (144 critically ill) primarily receiving standard-dose prophylactic anticoagulation, venous thromboembolism rate was 4.8%, and the overall thrombotic complication rate was 9.5%.<sup>13</sup> Current data suggest that COVID-19 can infect endothelial cells with an ensuing associated immune response and attendant activation of inflammatory pathways resulting in dysregulation of the endothelium, leukocyte activation, neutrophil extracellular traps generation (a matrix of DNA decorated with neutrophil granule proteins, such as myeloperoxidase, cathepsin G, and neutrophil elastase), complement deposition, and platelet activation and consumption [13]. It has been suggested that the virus instigates the process of pyroptosis, an inflammatory form of programmed cell death observed upon infection with intracellular pathogens, which could contribute to the endothelial cell death after COVID-19 infection and could increase proinflammatory cytokine releases, such as interleukin (IL)-1 beta and IL-18 [14].

Another study by Bozzani, *et al.* [15] analyzed 38 patients with severe COVID-19 infection (6 with lower limb arterial thrombosis and 32 with DVT). Among the patients with lower limb arterial thrombosis, 1 patient died from major organ failure and one patient underwent major amputation. The authors concluded that COVID-19 patients who develop arterial and deep vein thrombosis are at high risk of mortality. These data are very similar with those found in this paper, where among 4 cases, there was one death and one limb loss.

In this present paper the patient that had a fatal outcome (CASE 3) had HIV infection prior to COVID-19 infection. However, it is not clear if people living with HIV are at greater risk than the general population. Most of studies suggest that patients with HIV infection with well-controlled disease are not at risk of poorer COVID-19 disease outcomes than the general population [16,17].

Larger trials and papers related to COVID-19 and acute arterial ischemia are needed in order to better comprehension regarding the impact of this infection in vascular system. However, due to the urgent of this pandemic crisis, case reports series can bring valuable information in order to assure best medical treatment for patients with acute arterial occlusion and COVID-19 infection.

## Conclusion

COVID-19 pandemic crisis is a challenging situation that has increased the number of acute arterial thrombosis and embolism urgencies and emergencies surgeries in the vascular world. The four patients related in this paper bring valuable information regarding the impact of COVID-19 on micro and macrovascular system.

## Reference

- Howard DP, Banerjee A, Fairhead JF, Hands L, Silver LE (2015) Rothwell P.M. Oxford Vascular Study Population-based study of incidence, risk factors, outcome, and prognosis of ischemic peripheral arterial events: implications for prevention. *Circulation*. 132: 1805-15.
- de Athayde Soares R, Matiolo MF, Brochado Neto FC, Cury MVM, Duque de Almeida R, et al. (2019) Analysis of the results of endovascular and open surgical treatment of acute limb ischemia. *J Vasc Surg* 69: 843-849.
- Tang N, Li D, Wang X, Sun Z (2020) Abnormal coagulation parameters are associated with poor prognosis in patients with novel coronavirus pneumonia. *J Thromb Haemost* 18: 844-7.
- Han H, Yang L, Liu R, Liu F, Wu KL, et al. (2020) Prominent changes in blood coagulation of patients with SARS-CoV-2 infection. *Clin Chem Lab Med*.
- Bellosta R, Luzzani L, Natalini G, Pegorer MA, Attisani L, et al. (2020) Acute limb ischemia in patients with COVID-19 pneumonia. *J Vasc Surg* 5214: 31080-6.
- Ben Abdallah I (2020) Early experience in Paris with the impact of the COVID-19 pandemic on vascular surgery. *J Vasc Surg* 72: 373.
- Inessa A Goldman, Kenny Ye, Meir H (2020) Lower extremity arterial thrombosis associated with COVID-19 is characterized by greater thrombus burden and increased rate of amputation and death. *Radiology* 16: 202348.
- Grilz E, Königsbrügge O, Posch F, Schmidinger M, Pirker R, (2018) Frequency, Risk Factors, and Impact on Mortality of Arterial Thromboembolism in Patients with Cancer *Haematologica* 103:1549-56.
- Clerkin KJ, Fried JA, Raikhelkar J. COVID-19 and Cardiovascular Disease. *Circulation*. 2020;141(20):1648-1655.
- Kipshidze N, Dargas G, White CJ (2020) Viral coagulopathy in patients with COVID-19: treatment and care. *Clin Appl Thromb Hemost* 26: 1076029620936776.
- Connors JM, Levy JH (2020) COVID-19 and its implications for thrombosis and anticoagulation. *Blood* 135: 2033-40.
- Al-Samkari H, Karp Leaf RS, Dzik WH (2020) COVID-19 and coagulation: bleeding and thrombotic manifestations of SARS-CoV-2 infection. *Blood* 136: 489-500.
- McFadyen JD, Stevens H, Peter K (2020) The emerging threat of (Micro)thrombosis in COVID-19 and its therapeutic implications. *Circ Res* 127: 571-87.



14. Agashima S, Mendes MC, Camargo Martins AP (2020) Endothelial dysfunction and thrombosis in patients with COVID-19. *Arterioscler Thromb Vasc Biol* Atvbaha120314860.
15. Bozzani A, Arici V, Tavazzi G, Franciscone MF, Danesino V, et al. (2020) ACUTE ARTERIAL AND DEEP VENOUS THROMBOEMBOLISM IN COVID-19 PATIENTS. *Surgery*.
16. Coronavirus (COVID-19) and HIV – update from the British HIV Association (BHIVA). Available at <https://www.bhiva.org/BHIVA-statement-on-COVID-19>.
17. Cooper CL (2012) Pandemic H1N12009 Influenza and HIV: a review of natural history, management and vaccine immunogenicity. *Curr Opin Infect Dis* 25: 26–35.